

Systemic Inflammation Induced by Lipopolysaccharide Increases Neointimal Formation After Balloon and Stent Injury in Rabbits

Haim D. Danenberg, MD; Frederick G.P. Welt, MD; Matthew Walker III, PhD; Philip Seifert, MS; Greg S. Toegel, BA; Elazer R. Edelman, MD, PhD

Background—Emerging data indicate that the inflammatory response after mechanical arterial injury correlates with the severity of neointimal hyperplasia in animal models and postangioplasty restenosis in humans. The present study was designed to examine whether a nonspecific stimulation of the innate immune system, induced in close temporal proximity to the vascular injury, would modulate the results of the procedure.

Methods and Results—Rabbits subjected to iliac artery balloon injury (balloon denudation with or without stent deployment) were injected twice with a bacterial lipopolysaccharide (LPS) (500 ng/rabbit) before and after surgery. The dose was chosen to be sufficient to induce systemic inflammation but not septic shock. A systemic marker of inflammation (serum interleukin-1 β levels measured by ELISA) and monocytic stimulation (CD14 levels on monocytes measured by flow cytometry) were increased after LPS administration. Arterial macrophage infiltration at 7 days after injury was $1.7\pm 1.2\%$ of total cells in controls and $4.2\pm 1.8\%$ in LPS-treated rabbits ($n=4$, $P<0.05$). Morphometric analysis of the injured arteries 4 weeks after injury revealed significantly increased luminal stenosis ($38\pm 4.2\%$ versus 23 ± 2.6 , mean \pm SEM; $n=8$, $P<0.05$) and neointima-to-media ratio (1.26 ± 0.21 versus 0.66 ± 0.09 , $P<0.05$) in LPS-treated animals compared with controls. This effect was abolished by anti-CD14 Ab administration. Serum interleukin-1 β levels and monocyte CD14 expression were significantly increased in correlation with the severity of intimal hyperplasia. LPS treatment increased neointimal area after stenting from 0.57 ± 0.07 to 0.77 ± 0.1 mm² and stenosis from $9\pm 1\%$ to $13\pm 1.7\%$ ($n=5$, $P<0.05$).

Conclusions—Nonspecific systemic stimulation of the innate immune system concurrently with arterial vascular injury facilitates neointimal formation, and conditions associated with increased inflammation may increase restenosis. (*Circulation*. 2002;105:2917-2922.)

Key Words: balloon ■ stents ■ inflammation ■ leukocytes ■ restenosis

Intimal hyperplasia is a universal response of the arterial wall to mechanical injury, and it is a major cause of restenosis after percutaneous coronary interventions (PCIs). The multifactorial pathophysiology of restenosis remains as yet not entirely defined. Emerging experimental and clinical data indicate that inflammation is of major importance to the restenotic process.

Inflammatory cells are activated promptly after vascular injury¹ and recruited to the site of injury.²⁻⁵ These cells are capable of releasing mediators that facilitate smooth muscle cell (SMC) migration and proliferation.⁶⁻⁸ In human studies, the severity of postangioplasty luminal loss has been found to correlate with activation of circulating leukocytes,⁹ and restenosis in patients undergoing directional atherectomy has been determined to be correlated with the percentage of macrophages in retrieved tissue at the time of angioplasty.¹⁰ Recently, polymorphism of the gene for interleukin (IL)-1 receptor antagonist, a protein that regulates inflammatory

response, was found to be associated with reduced restenosis.¹¹ Several antiinflammatory strategies have successfully limited neointimal hyperplasia after injury in animal models. Deactivation of circulating monocytes by IL-10¹² and blocking leukocyte adhesion by use of an antibody (Ab) directed against the β_2 -integrin Mac-1 (CD11b/CD18)¹³ reduce neointimal formation after balloon injury and/or stent deployment in rabbits. Furthermore, vascular injury in Mac-1-deficient mice is associated with reduced leukocyte accumulation and reduced neointimal formation.¹⁴

The fundamental questions that arise are whether the stimulation of inflammation in vascular repair is specific or general and whether inflammation is localized to and controlled only at the site of injury alone or is responsive to systemic modulation. If injury is mediated by a specific inflammatory signal, then this specific pathway needs to be fully delineated and then targeted. Similarly, if the inflammatory process is local, then local therapy alone may suffice,

Received December 27, 2001; revision received March 28, 2002; accepted March 28, 2002.

From Harvard-MIT Division of Health Sciences and Technology, Massachusetts Institute of Technology, Cambridge, Mass.

Correspondence to Haim D. Danenberg, MD, MIT Building 56-322, 77 Massachusetts Ave, Cambridge, MA 02139. E-mail danen@mit.edu

© 2002 American Heart Association, Inc.

Circulation is available at <http://www.circulationaha.org>

DOI: 10.1161/01.CIR.0000018168.15904.BB

whereas systemic inflammation might require systemic therapy. Finally, a systemic nonspecific response would be sensitive to preexisting inflammation and other inflammatory events, whereas specific localized effects would not. The present study was designed to examine these issues. Rabbits subjected to iliac artery balloon injury, with or without stent deployment, were assigned to bacterial lipopolysaccharide (LPS) injection immediately before and 1 day after the procedure. We report that activation of the innate immune system by LPS is associated with an increased neointimal formation and luminal loss after vascular injury. Furthermore, this augmentation of neointimal growth is blocked by administration of a monoclonal Ab (mAb) directed against CD14.

Methods

Vascular Injury Model

Animal care and procedures were in accordance with the guidelines of the American Association for the Accreditation of Laboratory Animal Care and the National Institutes of Health. Male New Zealand White rabbits (Covance Products, Denver, Pa), 2.8 to 3.2 kg, were fed rabbit chow and water ad libitum. Under anesthesia with xylazine (5 mg/kg IM) and ketamine (35 mg/kg IM), the femoral arteries were exposed and ligated, and the iliac arteries were denuded of endothelium by the intraluminal passage of a 3F arterial embolotomy catheter (Baxter) passed to the abdominal aorta and withdrawn in the inflated state 3 times. In 10 animals, a 9-mm metallic stent (NIR 7 cell, Medinol) mounted on a 3×15-mm-long balloon was implanted in the right iliac artery (15-second inflation at 8 atm) immediately after denudation, resulting in marked arterial overstretch (stent-to-artery ratio 1.1:1 to 1.2:1). Heparin (100 U/kg IV) was administered immediately after arteriotomy, and animals were treated with aspirin (0.07 mg/mL in drinking water). LPS (*Escherichia coli* 0127:B8, Sigma) was injected (500 ng/rabbit IV) immediately before and 24 hours after injury. Arterial blood was collected into citrate-containing tubes at the time of the procedure and from the ear artery at 6 and 24 hours later. CD14 receptor blockade was performed by use of anti-rabbit CD14 mAb (generous gift of Dr R. Ulevich, La Jolla, Calif)¹⁵ injected (2.5 mg/kg IV) at days -1 and +5. Control animals were injected with murine IgG2a. Blockade of CD14 receptors was confirmed by flow cytometry analysis for CD14-positive blood monocytes.

Hemodynamics

The left common carotid artery was cannulated with a polyethylene catheter for blood pressure measurement (Gould Inc). Systemic blood pressure, heart rate, and respiratory rate were recorded under baseline conditions every minute for 30 minutes after LPS injection and at 30-minute intervals up to 8 hours.

Arterial Harvest and Analysis

Rabbits were euthanized by pentobarbital overdose. Iliac arteries were perfusion fixed with 10% neutral buffered formalin at physiological pressure. Balloon-injured arteries were embedded in paraffin, and 4 to 6 sections 5 μ m thick were cut from 3 equally spaced locations. Stented arteries were oriented longitudinally and embedded with a methacrylate formulation. Multiple 5- μ m-thick sections were cut with a tungsten carbide knife (Delaware Diamond Knives) on an automated microtome (Leica, Inc) from the proximal and distal ends and the midpoint of each stented segment. Measurements on Verhoeff's tissue elastin-stained sections were performed by use of Scion Image software (Scion Corp) running on a computer-assisted digital camera system (Sony Co) interfaced to a Nikon microscope. All sites were analyzed, and the results were averaged.

Immunohistochemistry

Species-specific antibodies were used to immunocytochemically identify macrophages (RAM 11, Dako Co). Rabbit spleen was used

as a positive control; a nonspecific isotype Ab was used as a negative control. Standard immunocytochemical protocols were used in conjunction with heat-induced epitope retrieval. Deparaffinized and rehydrated sections were heated in a microwave for 20 minutes in 1× Target Retrieval Solution (Dako), quenched with peroxidase, then incubated with the primary Ab (RAM-11 or nonspecific Ig) for 1 hour, followed by detection with the EnVision+ system (Dako). Sections were counterstained with Mayer's hematoxylin, then dehydrated and mounted. The RAM-11-positive cells, identified by brown staining, were divided by the total number of intimal and medial cells (3 sections for each slide).

Determination of Monocyte Activation

CD14 Expression on Monocytes

CD14 is a protein essential for LPS-induced cellular activation. CD14 expression is increased in the activated monocyte. The activation status of monocytes was examined in triplicate by fluorescence-activated cell sorting (FACS) with fluorescent anti-CD14 antibodies. Anticoagulated blood was incubated for 30 minutes (200 μ L, 4°C, in the dark) with mouse anti-human R-phycoerythrin-conjugated anti-CD14 (4 μ L, Dako). FACS lysing solution (Becton Dickinson) was added for 15 minutes, and the residual cells were washed 3 times in FACS medium (PBS, 1% BSA, 0.02% sodium azide) ($\times 1500$ rpm, 5 minutes, 4°C). Cells were then suspended in 1 mL of FACS medium, and flow cytometry was performed within 1 hour (Becton Dickinson flow cytometer). Monocytes were identified according to their forward- and side-scattering properties as well as fluorescence.

Serum IL-1 β Determination

IL-1 β is a major product of monocytes, secreted in response to LPS. Serum was separated and stored at -70°C until further analysis. After it was thawed, IL-1 β levels were measured in triplicate with a commercial ELISA kit (Biosource International).

Statistical Analysis

All data are presented as mean \pm SEM. Comparisons between treatment groups used an unpaired, 2-tailed *t* test. Values of *P* < 0.05 were considered significant.

Results

Effect of LPS on Balloon Injury-Induced Intimal Hyperplasia

Morphometric analysis of balloon-injured arteries at 28 days after injury revealed concentric neointimal hyperplasia in both control and LPS-treated animals (Figure 1, A–D). Neointimal area was increased by 48% in LPS-treated rabbits. Neointima-to-media (N/M) ratio and luminal stenosis were increased significantly, by 91% and 65%, respectively (Figure 1E). Luminal area was reduced by 29%. Total arterial area and medial area were reduced insignificantly in LPS-treated animals, by 12% and 20%, respectively. Arteries not injured by balloons revealed no histological difference between control and LPS-treated animals (data not shown). Administration of anti-CD14 Ab to balloon-injured animals did not affect neointimal growth. When it was administered to LPS-stimulated rabbits, the increase in neointimal growth was not significantly different from control levels (Figure 1E). Heart rate, blood pressure, and respiration were not changed significantly after injection of LPS.

Effect of LPS on Stent-Induced Intimal Hyperplasia

Not unexpectedly, intimal hyperplasia in control arteries implanted with NIR stents was relatively modest, with an

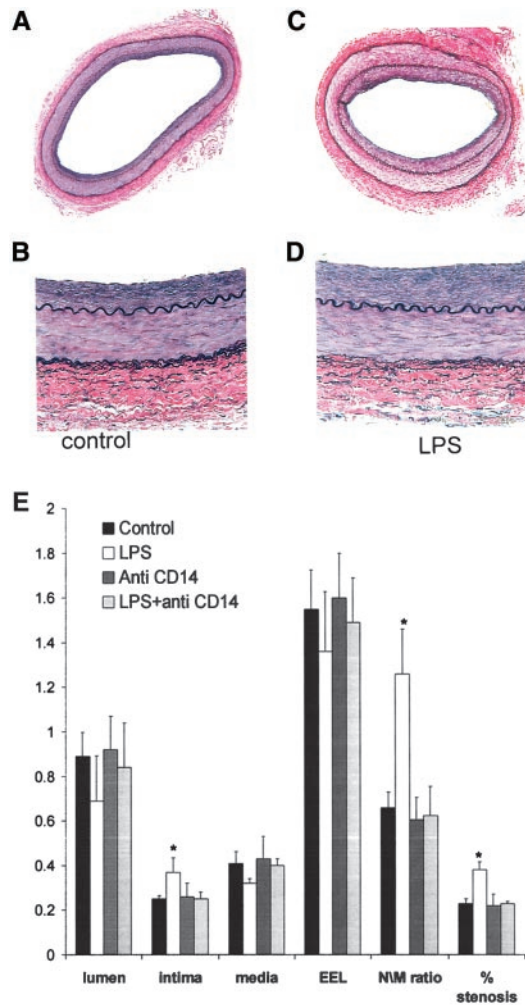


Figure 1. Intimal hyperplasia 28 days after balloon angioplasty. Lower- and higher-magnification photomicrographs (Verhoeff staining) of arterial sections from control (A and B) and LPS-treated (C and D) rabbits. Note thicker intima in LPS-treated rabbit. E, Bar graph showing increased intimal area, N/M ratio, and luminal cross-sectional area narrowing (% stenosis) in arteries of LPS-treated animals (n=6) vs control rabbits (n=8). Treatment with anti-CD14 blocked these LPS-induced effects but had no effect in control rabbits (n=4). *P=0.05.

intimal area of $0.57 \pm 0.07 \text{ mm}^2$ and stenosis of $9 \pm 1\%$. LPS treatment increased neointimal area significantly, by 35%, to $0.77 \pm 0.1 \text{ mm}^2$ and stenosis by 44%, to $13 \pm 1.7\%$ (Figure 2; n=5, $P < 0.05$ for both intimal area and stenosis). Medial area was unchanged and luminal area was reduced insignificantly by LPS (5.81 ± 0.6 and $5.2 \pm 0.33 \text{ mm}^2$, control and LPS-treated, respectively).

Immunohistochemical Staining for Leukocytes

Macrophage infiltration into the injured arterial wall was recorded at 7 days after injury. LPS administration resulted in an increase in RAM11-positive cells in the vessel wall from $1.7 \pm 1.2\%$ of total cells to $4.2 \pm 1.8\%$ (Figure 3; n=4, $P < 0.05$).

CD14 Expression on Blood Monocytes

CD14 expression on circulating monocytes was increased significantly in LPS-treated animals compared with injured

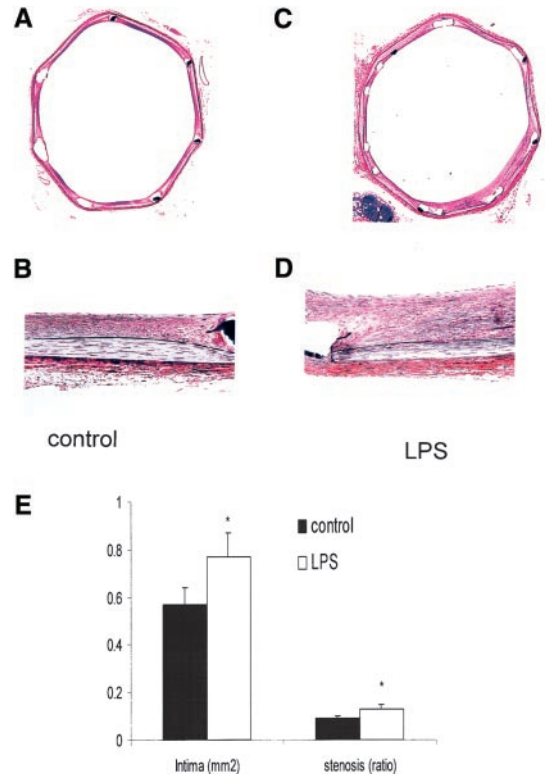


Figure 2. Intimal hyperplasia 28 days after stent deployment. Lower- and higher-magnification photomicrographs (Verhoeff staining) of arterial sections from control (A and B) and LPS-treated (C and D) rabbits. Note thicker intima in LPS-treated rabbit. E, Bar graph showing increased intimal area and luminal cross-sectional area narrowing (% stenosis) in arteries of LPS-treated animals vs control rabbits (n=5). *P<0.05.

controls. At 6 hours after vascular injury, there was a $120 \pm 25\%$ increase in CD14 expression after LPS treatment, whereas no change was recorded in controls (n=4; Figure 4). Expression at 24 hours was increased by 64% and 30% in LPS-treated animals and controls, respectively. Anti-CD14 Ab administration was associated with complete disappear-

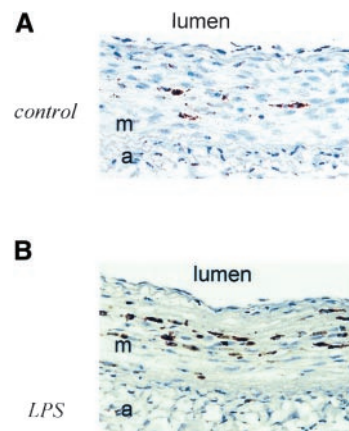


Figure 3. Macrophage infiltration 7 days after balloon angioplasty. RAM-11-immunostained arterial sections ($\times 20$ magnification) from control and LPS-treated rabbits. Brown cytoplasmic stain indicates macrophages; m, media; and a, adventitia. RAM-11-positive cells were from $1.7 \pm 1.2\%$ of total arterial wall cells in controls and $4.2 \pm 1.8\%$ in LPS-treated rabbits (n=4), $P < 0.05$.

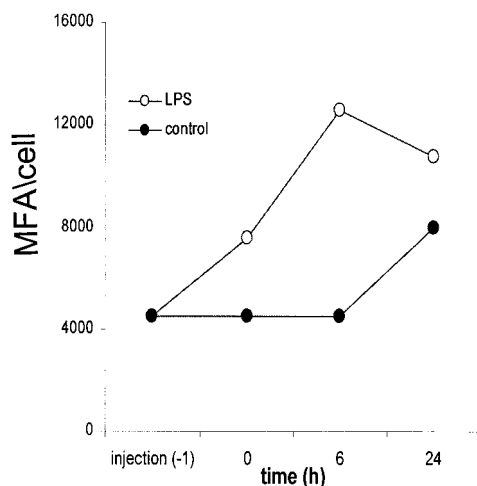


Figure 4. Monocyte activation after balloon injury. Line graph of a representative flow cytometry analysis for CD14 expression on peripheral blood monocytes in control and LPS-treated rabbits. MFA indicates median fluorescent activity.

ance of CD14-positive monocytes at 24 hours after injection (data not shown).

Serum IL-1 β

IL-1 β levels in serum were increased at 6 hours after injury in both control and LPS-treated rabbits. At 24 hours after injury, IL-1 β levels were increased by 79% over baseline levels in LPS-treated animals (Figure 5A) and reduced by

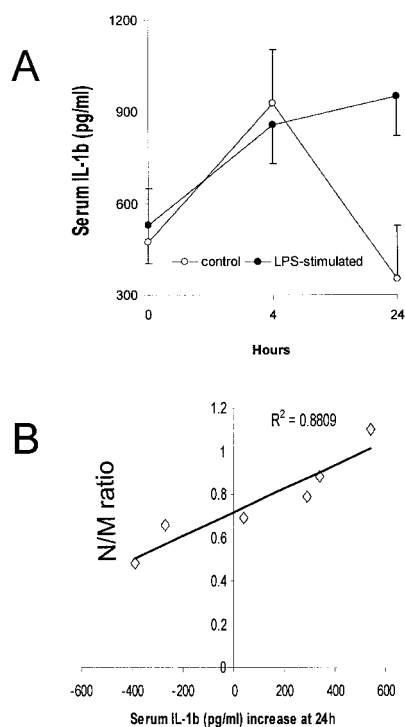


Figure 5. Serum IL-1 β after injury and relation to intimal hyperplasia. A, Serum IL-1 β levels after vascular injury in control and LPS-treated rabbits ($n=3$, $P<0.05$). B, Correlation between IL-1 β serum level increase at 24 hours and N/M ratio at 28 days in control and LPS-treated animals.

25% in controls (from 530 ± 163 to 950 ± 53 pg/mL and 474 ± 273 to 352 ± 162 pg/mL, LPS and control, respectively, mean \pm SD; $n=3$ in each group; $P=0.016$). To examine the predictive value of early nonspecific stimulation of the innate immune system on late intimal hyperplasia, the serum IL-1 β change over baseline at 24 hours after injury was correlated with the N/M ratio at 30 days. A strong positive correlation was demonstrated ($r^2=0.88$), with the highest increase in IL-1 β associated with the maximal N/M ratio (Figure 5B).

Discussion

Inflammation is essential to neointimal formation after experimental vascular injury and restenosis after percutaneous clinical vascular intervention. Leukocytes are central promoters and constituents of intimal proliferation, and vascular injury of many forms evokes a marked inflammatory state¹ that correlates with subsequent restenosis.⁹ What has not been clear until now is whether the exacerbation of vascular injury by inflammation is a local phenomenon restricted to the site of injury alone or whether global and systemic inflammation, even of a nonspecific and preexisting nature, might contribute as well. It is as yet undefined whether systemic inflammatory mediators, such as C-reactive protein, that correlate with restenosis¹⁶ are markers of increased risk or are causative in and of themselves. The present study demonstrates that LPS administration leads to increased neointimal growth, probably via systemic, nonspecific activation of leukocytes. Correlation was found between systemic inflammation, as measured by blood IL-1 β levels, and late intimal growth.

Monocytes, macrophages, and neutrophils are immediately activated in response to infection and injury,¹⁷ including vascular mechanical injury.¹ Neutrophils infiltrate an injured vessel wall rapidly, followed by monocytes.³⁻⁵ Adaptive T lymphocyte-mediated immune responses are probably not involved in neointimal proliferation after balloon dilatation.¹⁸ Thrombin-activated platelets and increased monocyte chemoattractant protein-1 expression by injured endothelial cells are among the stimuli that activate monocytes after vascular injury. Macrophages express numerous growth factors, cytokines, and enzymes that facilitate SMC migration and proliferation.⁸ Systemic modulation of macrophage function inhibits neointimal formation by various modalities, including IL-10 deactivation of monocytes¹² and mAb blockade of Mac-1, a β_2 -integrin expressed on leukocytes.¹³

LPS administration stimulates blood monocytes, which increases production and secretion of growth factors. When administered with vascular balloon injury, LPS activated blood monocytes, increased systemic production of IL-1 β , and increased local vascular infiltration of macrophages, all associated with increased intimal hyperplasia. Even in an injury model in which the hyperplastic response is minimal, ie, after implantation of clinically available stents, LPS increased both inflammation and injury. Both systemic secretion of inflammatory mediators and/or increased arrival of highly activated monocytes to the site of injury may explain increased intimal growth. The early increase in serum IL-1 β and its correlation with further intimal growth may indicate that systemic secretion is associated with the late growth effect, whereas the increased macrophage infiltration sup-

ports a local effect. The 2 mechanisms, however, may be interrelated. The proinflammatory cytokine IL-1 β increases adhesion of leukocytes to SMCs through increased expression of intercellular adhesion molecule-1 and CD 44 and increases IL-6 production by SMCs. Thus, IL-1 β may indirectly affect SMC activation and proliferation and matrix formation, positively correlating with postinjury neointimal formation.

LPS affects cells involved in healing of vascular injury other than CD14-positive leukocytes. It can cause endothelial vacuolization and desquamation^{19,20} at much higher doses than those used in this study and increases intercellular adhesion molecule-1 expression on these cells.²¹ LPS induces the expression of procoagulant tissue factor in epithelial cells²² and activates vascular SMCs,²³ probably through soluble CD14 receptors.²³ In the present study, blockade of these receptors by mAbs abolished the enhanced formation of neointima after LPS. Thus, additional mechanisms other than the activation of CD14-positive monocytes may underlie the effect observed in this study. Interestingly, total blockade of CD14 in animals not treated with LPS had no effect on neointimal formation (Figure 1E). Thus, the inflammatory response that can affect vascular healing is secondary to several different stimuli, of which CD14-activation is but one.

Although “nonspecific” antiinflammatory drugs effectively reduce neointimal formation and restenosis after experimental vascular injury in a wide variety of models, their effects have not been reproduced in randomized clinical trials. The discrepancy and lack of clinical efficacy may result from inadequate dosing²⁴; from the increased inflammation associated with the surgery performed in animals before arteriotomy, unlike the “minimal” percutaneous procedure performed in humans; or from the large burden of inflammatory cells already present in human atherosclerotic lesions and the inability of the antiinflammatory regimen to block the acute-phase innate response. In 2 clinical trials in which systemic glucocorticoids failed to affect restenosis, methylprednisolone was injected <24 hours before PCI with²⁵ or without²⁶ continuous steroid therapy. This mode of administration may initially stimulate macrophages,^{27,28} and it may be that the rapid macrophage trafficking to the injured vessel⁵ requires a more immediate and macrophage-specific systemic antiinflammatory protocol.

The association of a nonspecific inflammatory response and increased neointimal formation may have relevance for certain clinical situations associated with higher rates of adverse outcome, such as end-stage renal failure and dialysis,²⁹ both of which involve constant activation and phenotypic modulation of monocytes³⁰ that may affect their activity when recruited to the site of injury.

Systemic inflammation caused by infection, unrelated to the vascular injury, can modify the healing process. Cytomegalovirus infection increased neointimal formation after balloon injury,³¹ probably via systemic inflammatory changes.³² On the basis of the present study, we may assume that the inflammatory response that affects vascular healing is not pathogen specific.

Clinical or subclinical bacteremia may accompany up to 8% of PCIs.^{33,34} Although completely asymptomatic and subclinical, such bacteremia may stimulate the innate immune system, which in turn affects the long-term results of PCI. Thus, special caution regarding the prevention and detection of infection is warranted.

In conclusion, nonspecific systemic stimulation of the innate immune system concurrently with arterial injury is associated with increased neointimal formation, creating a cycle of injury and inflammation, which contribute to and stimulate each other. These findings add to our understanding of how the outcome of PCIs may differ, the lack of correlation between experimental and clinical studies, and how systemic inflammation should be considered and minimized whenever possible in the setting of intracoronary interventions.

References

- Serrano C, Ramires J, Venturinelli M, et al. Coronary angioplasty results in leukocyte and platelet activation with adhesion molecules expression: evidence of inflammatory responses in coronary angioplasty. *J Am Coll Cardiol*. 1997;29:1276–1283.
- Hancock W, Adams D, Wyner L, et al. CD4+ mononuclear cells induce cytokine expression, vascular smooth muscle cell proliferation, and arterial occlusion after endothelial injury. *Am J Pathol*. 1994;145:1008–1014.
- Welt FGP, Edelman ER, Simon DI, et al. Neutrophil, not macrophage, infiltration precedes neointimal thickening in balloon-injured arteries. *Arterioscler Thromb Vasc Biol*. 2000;20:2553–2558.
- Wilensky R, March K, Gradus-Pizlo I, et al. Vascular injury, repair, and restenosis after percutaneous transluminal angioplasty in the atherosclerotic rabbit. *Circulation*. 1995;92:2995–3005.
- Okamoto E, Couse T, De Leon H, et al. Perivascular inflammation after balloon angioplasty of porcine coronary arteries. *Circulation*. 2001;104:2228–2235.
- Jawien A, Bowen-Pope DF, Lindner V, et al. Platelet-derived growth factor promotes smooth muscle migration and intimal thickening in a rat model of balloon angioplasty. *J Clin Invest*. 1992;89:507–511.
- Bendeck MP, Nobuya Z, Clowes AW, et al. Smooth muscle cell migration and matrix metalloproteinase expression after arterial injury in the rat. *Circ Res*. 1994;75:539–545.
- Libby P, Schwartz D, Brogi E, et al. A cascade model for restenosis: a special case of atherosclerosis progression. *Circulation*. 1992;86(suppl III):III-47–III-52.
- Pietersma A, Koflard M, de Wit LE, et al. Late lumen loss after coronary angioplasty is associated with the activation status of circulating phagocytes before treatment. *Circulation*. 1995;91:1320–1325.
- Moreno P, Bernardi V, Lopez-Cuellar J, et al. Macrophage infiltration predicts restenosis after coronary intervention in patients with unstable angina. *Circulation*. 1996;94:3098–3102.
- Kastrati A, Koch W, Berger PB, et al. Protective role against restenosis from an interleukin-1 receptor antagonist gene polymorphism in patients treated with coronary stenting. *J Am Coll Cardiol*. 2000;36:2168–2173.
- Feldman L, Aguirre L, Ziolo M, et al. Interleukin-10 inhibits neointimal hyperplasia after angioplasty or stent implantation in hypercholesterolemic rabbits. *Circulation*. 2000;101:908–916.
- Rogers C, Edelman ER, Simon DI. A mAb to the β_2 -leukocyte integrin Mac-1 (CD11b/CD18) reduces intimal thickening after angioplasty or stent implantation in rabbits. *Proc Natl Acad Sci U S A*. 1998;95:10134–10139.
- Simon D, Chen Z, Seifert P, et al. Decreased neointimal formation in Mac-1 $^{-/-}$ mice reveals a role for inflammation in vascular repair after angioplasty. *J Clin Invest*. 2000;105:293–300.
- Schimke J, Mathison J, Morgiewicz J, et al. Anti-CD14 mAb treatment provides therapeutic benefit after in vivo exposure to endotoxin. *Proc Natl Acad Sci U S A*. 1998;95:13875–13880.
- Buffon A, Liuzzo G, Biasucci L, et al. Preprocedural serum levels of C-reactive protein predict early complications and late restenosis after coronary angioplasty. *J Am Coll Cardiol*. 1999;34:1512–1521.

17. Medzhitov R, Janeway C. Advances in immunology: innate immunology. *N Engl J Med*. 2000;343:338–344.
18. Andersen H, Hansen B, Holm P, et al. Effect of cyclosporine on arterial balloon injury lesions in cholesterol-clamped rabbits: T lymphocyte-mediated immune responses not involved in balloon injury-induced neointimal proliferation. *Arterioscler Thromb Vasc Biol*. 1999;19:1687–1694.
19. Reidy M, Schwartz S. Endothelial injury and regeneration, IV: endotoxin: a nonhealing injury to aortic endothelium. *Lab Invest*. 1983;48:25–34.
20. Nayyar R, Hurley R, Goto M, et al. Microvascular endothelium: a major target site of endotoxin induced injury in 10 day old rat. *J Exp Pathol*. 1989;4:57–67.
21. Lush C, Cepinskas G, Kviety P. LPS tolerance in human endothelial cells: reduced PMN adhesion, E-selectin expression, and NF-kappaB mobilization. *Am J Physiol*. 2000;278:H853–H861.
22. Ehrlich J, Fearn C, Mathison J, et al. Lipopolysaccharide induction of tissue factor expression in rabbits. *Infect Immun*. 1999;67:2540–2546.
23. Loppnow H, Stelter F, Schonbeck U, et al. Endotoxin activates human vascular smooth muscle cells despite lack of expression of CD14 mRNA or endogenous membrane CD14. *Infect Immun*. 1995;63:1020–1026.
24. Voisard R, Fischer R, Obwald M, et al. Aspirin (5 mmol/L) inhibits leukocyte attack and triggered reactive cell proliferation in a 3D human coronary in vitro model. *Circulation*. 2001;103:1688–1694.
25. Stone GW, Rutherford BD, McConahay DR, et al. A randomized trial of corticosteroids for the prevention of restenosis in 102 patients undergoing repeat coronary angioplasty. *Cathet Cardiovasc Diagn*. 1989;18:227–231.
26. Pepine CJ, Hirshfeld JW, Macdonald RG, et al. A controlled trial of corticosteroids to prevent restenosis after coronary angioplasty. M-HEART Group. *Circulation*. 1990;81:1753–1761.
27. van der Goes A, Hoekstra K, van den Berg TK, et al. Dexamethasone promotes phagocytosis and bacterial killing by human monocytes/macrophages in vitro. *J Leukoc Biol*. 2000;67:801–807.
28. Fingerote RJ, Abecassis M, Phillips MJ, et al. Loss of resistance to murine hepatitis virus strain 3 infection after treatment with corticosteroids is associated with induction of macrophage procoagulant activity. *J Virol*. 1996;70:4275–4282.
29. Azar R, Prpic R, Ho K, et al. Impact of end-stage renal disease on clinical and angiographic outcomes after coronary stenting. *Am J Cardiol*. 2000;86:485–489.
30. Brauner A, Lu Y, Hallden G, et al. Difference in the blood monocyte phenotype between uremic patients and healthy controls: its relation to monocyte differentiation into macrophages in the peritoneal cavity. *Inflammation*. 1998;22:55–66.
31. Zhou Y, Shou M, Guetta E, et al. Cytomegalovirus infection of rats increases the neointimal response to vascular injury without consistent evidence of direct infection of the vascular wall. *Circulation*. 1999;100:1569–1575.
32. Lemstrom K, Bruning J, Bruggerman C, et al. Triple drug immunosuppression significantly reduces immune activation and allograft arteriosclerosis in cytomegalovirus-infected rat aortic allografts and induces early latency of viral infection. *Am J Pathol*. 1994;144:1334–1347.
33. Shea K, Schwartz R, Gambino A, et al. Bacteremia associated with percutaneous transluminal coronary angioplasty. *Cathet Cardiovasc Diagn*. 1995;36:5–9.
34. Samore M, Wessolossky M, Lewis S, et al. Frequency, risk factors, and outcome for bacteremia after percutaneous transluminal coronary angioplasty. *Am J Cardiol*. 1997;79:873–877.