

Inflammation and Restenosis in the Stent Era

Frederick G.P. Welt, Campbell Rogers

Abstract—The pathophysiology of restenosis involves early elements of direct injury to smooth muscle cells, deendothelialization, and thrombus deposition. Over time, this leads to smooth muscle cell proliferation/migration and extracellular matrix deposition. There is an increasing body of evidence to suggest that inflammation plays a pivotal role linking early vascular injury to the eventual consequence of neointimal growth and lumen compromise. The widespread use of coronary stents has fundamentally altered the vascular response to injury by causing a more intense and prolonged inflammatory state. Many of the cellular and molecular elements responsible for leukocyte recruitment have been elucidated, providing potential therapeutic targets for restenosis. This review seeks to provide an integrated view of the pathophysiology of restenosis that explains the central role of inflammation. (*Arterioscler Thromb Vasc Biol.* 2002;22:1769-1776.)

Key Words: stenting ■ balloon angioplasty ■ restenosis ■ inflammation

Since the first reports of successful angioplasty of human coronary atherosclerotic lesions, restenosis has been encountered as a significant limitation to the long-term efficacy of the procedure. In their 1979 landmark publication "Non-Operative Dilatation of Coronary-Artery Stenosis," Gruntzig et al¹ reported that 6 of 32 patients undergoing successful initial angioplasty suffered restenosis, a rate of 19%. Subsequent large-scale registries documented a restenosis rate closer to 33%.² Early histological studies of specimens retrieved from human necropsy specimens recognized a predominantly fibrocellular response at sites of prior angioplasty.³ Early animal studies revealed initial endothelial denudation, medial dissection, and platelet deposition as an immediate response to balloon injury and described late restenosis as a consequence of smooth muscle cell (SMC) proliferation and organized intraluminal thrombosis.^{4,5} Based on these understandings, early attempts to limit restenosis focused on antithrombotic and antiproliferative agents, but there was limited success in animal models and no success in human trials.⁶ In 1991, Forrester et al⁷ proposed a paradigm for restenosis based on the vascular biology of wound healing and suggested 3 phases in the process: an inflammatory phase, a granulation or cellular proliferation phase, and a phase of remodeling involving extracellular matrix protein synthesis. Subsequent studies have supported a critical role for inflammatory cells in the restenotic process and have uncovered a critical role for the thrombotic cascade in the initial recruitment of these inflammatory cells. As this fundamental understanding of restenosis after balloon angio-

plasty has developed, however, the clinical practice of interventional cardiology has undergone a profound change with the advent of intracoronary stenting. What has been perhaps underappreciated in the evolving understanding of restenosis from animal model and clinical perspectives is the profound impact that a chronic indwelling stent has on the vascular biological response to coronary intervention, particularly the impact on the inflammatory response.

Studies of restenosis in humans are limited by the fact that direct tissue examination is only rarely possible. Therefore, indirect measures of site-specific pathophysiological processes are the mainstay of this research. Animal studies allow direct examination of tissue and the ability to vary experimental conditions. However, animal models are not perfect mirrors of human pathology, and as proof, there are numerous examples of therapies that are effective in animals but not in humans. Therefore, animal studies are best used to answer specific biological questions that give insight into human disease rather than to provide exact surrogates of human pathology. The present review seeks to provide an integrated view of the pathophysiology of restenosis explaining the central role of inflammation. Evidence from animal and human studies of the importance of inflammation is described; also described are mechanisms of inflammatory cell recruitment and how these processes might be targeted to prevent restenosis. In addition, we discuss how endovascular stenting fundamentally affects the pathophysiological responses to vascular injury, with emphasis on the inflammatory responses.

Received March 25, 2002; revision accepted August 26, 2002.

From the Department of Medicine (F.G.P.W., C.R.), Cardiac Catheterization Laboratory and Coronary Care Unit, Cardiovascular Division, Brigham and Women's Hospital, Harvard Medical School, Boston, Mass; the Harvard-MIT Division of Health Sciences and Technology (F.G.P.W., C.R.), Massachusetts Institute of Technology, Cambridge, Mass; and the West Roxbury Veteran's Affairs Medical Center (F.G.P.W.), West Roxbury, Mass.

Correspondence to Frederick G.P. Welt, MD, Harvard-MIT Division of Health Sciences and Technology, MIT, 16-343, 77 Massachusetts Ave, Cambridge, MA 02139. E-mail welt@mit.edu

© 2002 American Heart Association, Inc.

Arterioscler Thromb Vasc Biol. is available at <http://www.atvbaha.org>

DOI: 10.1161/01.ATV.0000037100.44766.5B

Mechanisms of Leukocyte Recruitment and Infiltration

Leukocyte recruitment and infiltration occur at sites of vascular injury where the lining endothelial cells have been denuded and platelets and fibrin have been deposited. In vivo studies have shown that leukocytes and platelets colocalize at sites of hemorrhage, within atherosclerotic and postangioplasty restenotic lesions, and in areas of ischemia/reperfusion injury. This interaction between platelets and leukocytes appears to be critical to the inflammatory response.^{8,9}

A paradigm of leukocyte attachment to and transmigration across surface-adherent platelets has been proposed.¹⁰ The initial loose association to platelets and rolling of leukocytes is mediated by platelet P-selectin.¹¹ This is followed by their firm adhesion and transplatelet migration, processes that are dependent on the integrin class of adhesion molecules.¹⁰ The β_2 integrin molecule Mac-1 (CD11b/CD18) is present on neutrophils and monocytes and appears to be of central importance in leukocyte recruitment after vascular injury. In addition to promoting the accumulation of leukocytes at sites of vascular injury, the binding of platelets to neutrophils amplifies the inflammatory response by inducing neutrophil activation, upregulating cell adhesion molecule expression, and generating signals that promote integrin activation and chemokine synthesis. Interestingly, neutrophil-platelet and monocyte-platelet aggregates have been identified in the peripheral blood of patients with coronary artery disease and may be markers of disease activity.^{12,13}

Also central to the recruitment of leukocytes to areas of vascular injury, chemokines are a group of chemoattractant cytokines produced by a variety of somatic cells, including SMCs, endothelial cells, and leukocytes. One such chemokine of the C-C class, monocyte chemoattractant protein (MCP)-1, participates in the recruitment of monocytes (as well as basophils and certain activated T cells).¹⁴ The C-X-C chemokine, interleukin (IL)-8, plays a critical role in the recruitment of leukocytes to areas of vascular injury. It is well known that IL-8 is a pivotal cytokine in the recruitment of neutrophils.¹⁵ More recent evidence suggests that the murine analogue of IL-8, KC, also plays a critical role in the recruitment of monocytes to injured areas.¹⁶

Human Evidence for Role of Inflammation in Restenosis

It has long been recognized that restenosis is not a case of accelerated atherosclerosis but is rather a distinct temporal and pathophysiological process. Yet evidence has emerged indicating that leukocytes play a central role in atherogenesis and restenosis. A role for leukocytes in the pathogenesis of atherosclerosis has long been accepted. This is largely based on numerous human histopathological studies in which leukocytes, mainly of the monocyte lineage, have been identified at all stages of development of the atherosclerotic plaque, from fatty streaks to mature atheroma.¹⁷ Similar observations regarding restenosis have been hampered by the difficulty of obtaining human restenotic tissue. Farb et al¹⁸ recently reported findings from pathological studies of 116 stents from 87 patients >90 days after the procedure. They found a strong link between the extent of medial damage, inflammation, and

restenosis. Further crucial evidence linking leukocytes and restenosis has been provided by the study of Moreno et al,¹⁹ in which the authors obtained tissue from directional atherectomy catheters at the time of angioplasty and found a strong positive correlation between the number of macrophages present in the tissue at the time of angioplasty and the subsequent propensity for restenosis.

Given the difficulty of obtaining human restenotic tissue, many investigators have looked at systemic markers of inflammation after angioplasty. Neumann et al²⁰ devised a technique in which they collected blood samples proximal to and just distal to the site of balloon dilatation in humans. They performed flow cytometry to determine the expression of the neutrophil adhesion molecules L-selectin and CD11b and found an upregulation of these markers of leukocyte activation after angioplasty, measured as a gradient between distal and proximal specimens. Mickelson et al²¹ used systemic venous specimens from patients undergoing angioplasty and found flow cytometric evidence of the upregulation of CD11b on neutrophils and monocytes that correlated with a propensity for adverse clinical events. Inoue et al²² extended these observations to demonstrate that elevated levels of neutrophil CD11b are predictive of future propensity for restenosis in patients undergoing balloon angioplasty. Pietersma et al²³ showed that IL-1 production by stimulated monocytes of blood from patients before angioplasty predicted later luminal loss, whereas activation of granulocytes, measured by CD66 levels, was inversely correlated with late loss. Cipollone et al²⁴ demonstrated upregulated levels of MCP-1 after percutaneous intervention in humans and found that MCP-1 levels were correlated with a risk for restenosis. More recently, Gaspardone et al²⁵ showed a correlation between C-reactive protein (a nonspecific inflammatory marker) after stent placement and a propensity for restenosis.

Animal Model Evidence for Role of Inflammation in Restenosis

In experimental animal models, cell adhesion molecules critical for leukocyte recruitment have been found to be upregulated by an atherogenic diet,^{26–28} diabetes,²⁹ and increased shear stress.³⁰ In addition, vascular cell adhesion molecule-1, intercellular adhesion molecule-1, and major histocompatibility complex class II antigens have all been shown to be upregulated in a sustained fashion after balloon injury in the rabbit.³¹ Our laboratory has demonstrated that in animal models in which an endovascular stent is placed to produce deep trauma to the vessel, a particularly brisk early inflammatory response is induced with abundant surface adherent leukocytes of monocyte and granulocyte lineage.^{32,33} Days and weeks later, macrophages invade the forming neointima and are observed clustering around stent struts, forming giant cells. Blockade of early monocyte recruitment with anti-inflammatory agents results in reduced late neointimal thickening.^{32,34,35} As a corollary, a linear relationship exists between tissue monocyte content and neointimal area, suggesting a pivotal causal role for monocytes in restenosis.³² Activated macrophages are thought to influence vascular repair by producing a variety of mediators, including members of the interleukin family, tumor necrosis

factor, MCP-1, and growth factors, such as platelet-derived growth factors, basic fibroblast growth factor, and heparin-binding epidermal growth factor.³⁶

Several studies have also shown infiltration of neutrophils within the arterial wall after vascular injury.^{37–39} We recently reported the presence of neutrophils within the media and neointima of injured rabbit iliac arteries and demonstrated concomitant reductions in neutrophil number and medial smooth muscle proliferation with administration of anti-inflammatory agents.³³ The mechanisms by which neutrophils may affect vascular repair are not fully understood. Although neutrophils are not known to secrete growth factors per se, they do contribute to tissue injury through the release of reactive oxygen species and proteases.³⁶ Neutrophils are known to secrete cytokines, including IL-1, tumor necrosis factor- α , and IL-6.⁴⁰ In addition, it has been reported that rabbit vascular smooth cells are stimulated to proliferate when they are cocultured with neutrophils or neutrophil-conditioned media.⁴¹

Differences Between Balloon and Stent Injury

A major advance in the care of the patient undergoing cardiac intervention in the past decade has been the introduction of the coronary stent. This device has dramatically improved acute results and has reduced the incidence of subsequent restenosis. Still, in-stent restenosis, although less frequent, affects $\approx 20\%$ of patients and is often recalcitrant and costly to treat. What has emerged from systematic investigation in human and animal studies are profound differences between vascular biological responses to balloon- and stent-induced injury.

Human Studies of the Pathophysiology of In-Stent Versus Balloon Angioplasty Restenosis

The use of intravascular ultrasound to study restenotic lesions has been invaluable in the elucidation of mechanisms of restenosis. Studying restenosis after balloon angioplasty, Mintz et al⁴² used intravascular ultrasound to determine the contributions of neointimal hyperplasia and negative remodeling. They found that although negative remodeling (as measured by external elastic membrane area) and neointimal hyperplasia (as measured by plaque plus media cross-sectional area) contributed to restenosis, negative remodeling contributed substantially more (Figure 1). Angiographic analysis of the 2 first pivotal studies of coronary stents in humans (Stent Restenosis Study [STRESS]⁴³ and Belgian Netherlands Stent Study [BENESTENT]⁴⁴) revealed distinct qualitative and quantitative differences between balloon-injured and stented arteries. Stented arteries experienced a much larger initial lumen gain, which was presumably due to the rigid scaffolding provided by the stent that prevents acute elastic recoil. At follow-up, the luminal area was greater and binary restenosis was less in stented arteries than in balloon-angioplastied arteries. However, somewhat counterintuitively, late loss (lumen immediately after follow-up minus lumen at follow-up) was greater in stented arteries. Tying these observations together, stents incur greater neointimal growth, with their net benefit being attrib-

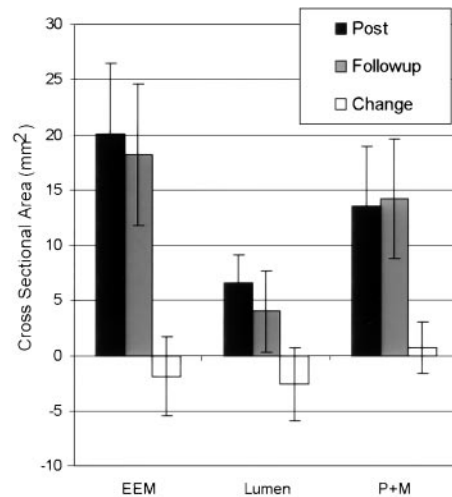


Figure 1. Graph of intravascular ultrasound measurements after balloon angioplasty. The arterial size, as measured by the cross-sectional area of the external elastic membrane (EEM), shrinks (remodels) over time, contributing more to the decrement in lumen size than does neointimal growth, as measured by the cross-sectional area of the plaque plus media (P+M). Adapted from Mintz et al.⁴²

utable to their larger initial lumen gain and prevention of remodeling. This was confirmed with a serial intravascular ultrasound study conducted by Hoffman et al⁴⁵ (Figure 2).

Although direct measures of inflammation at the site of clinical percutaneous intervention are virtually impossible, evidence has been gathered to suggest that there are differences in the inflammatory responses to stent placement and balloon angioplasty. Inoue et al⁴⁶ have used flow cytometry to measure CD11b expression on neutrophils after percutaneous coronary intervention and have found substantially higher levels on neutrophils from patients undergoing stent implantation compared with patients

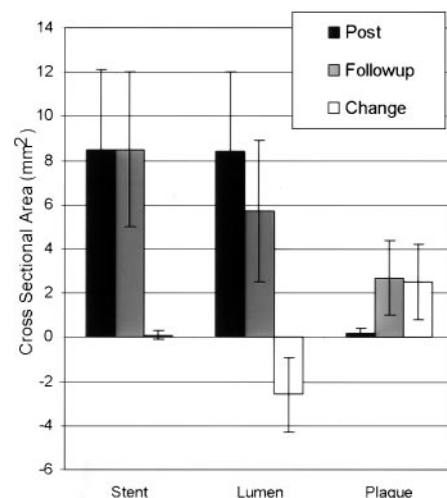


Figure 2. Graph of intravascular ultrasound measurements after stent placement. The arterial size, as measured by stent cross-sectional area, stays fixed over time, indicating no remodeling. The decrement in lumen size is entirely caused by neointimal growth, as measured by plaque cross-sectional area. Adapted from Hoffmann et al.⁴⁵

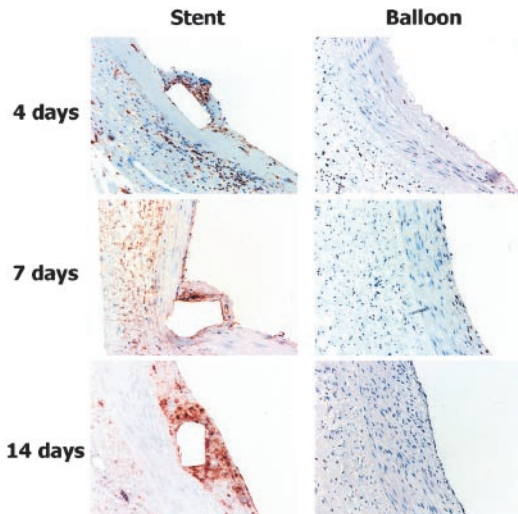


Figure 3. Immunohistochemical identification of macrophages within primate iliac arteries injured with either stents or balloon injury alone. Note that there is a steady accumulation of macrophages within stented segments with clustering of macrophages surrounding stent struts, whereas there is virtually no accumulation within the balloon-injured segments. From Horvath et al.⁵²

undergoing balloon angioplasty alone. This increased inflammatory response may help to explain the larger neointimal growth seen in stented arteries.

Animal Studies of the Pathophysiology of In-Stent Versus Balloon Angioplasty Restenosis

Several animal studies have demonstrated marked differences in response to vascular injury between balloon- and stent-induced injury, with specific emphasis on differences in the inflammatory response. Heparin, an archetypal modulator of vascular repair in animal models, has long been known to reduce neointimal growth after vascular injury.^{47,48} Heparin is equally effective at reducing neointimal hyperplasia after balloon injury or stent implantation.^{49,50} However, our laboratory has shown that maximal inhibition of neointimal hyperplasia in stented arteries requires continuous heparin administration for the duration of the experiment, whereas transient early heparin therapy after balloon injury is just as effective as chronic administration.⁵⁰ An explanation of this difference is suggested by further studies from our laboratory. In stented arteries, there is abundant recruitment of macrophages within the neointima (Figure 3). Inhibition of macrophage accumulation parallels reduction in neointimal growth.³² In contrast, in balloon-injured rabbit iliac arteries, a model devoid of macrophage infiltration (Figure 3), neutrophil infiltration has been documented within hours of injury. Inhibition of neutrophil infiltration is correlated with an inhibition of medial SMC proliferation.³³ To elucidate the mechanisms behind these differences, we determined mRNA levels of the monocyte chemokine MCP-1 and the neutrophil chemokine IL-8 at sites of vascular injury by using semiquantitative reverse transcriptase–polymerase chain reaction. In balloon injury, there was only transient expression (lasting only hours) of MCP-1 and IL-8. In contrast, in stented

arteries, there was sustained expression of IL-8 and, more prominently, MCP-1 as late as 14 days.⁵¹

We have been able to exploit these differences in inflammatory response with leukocyte-specific therapies. In a primate iliac artery model, monocyte-specific blockade, achieved via blockade of the MCP-1 receptor CCR2, was effective at reducing neointimal hyperplasia within stented segments of the arteries.⁵² In contrast, blockade of CCR2 was not effective against neointimal hyperplasia within balloon-injured segments. For balloon-injured segments, neutrophil blockade, achieved by targeting the leukocyte β_2 -integrin β -subunit CD18, was required to reduce neointimal hyperplasia. These data suggest not only that leukocyte infiltration is causally related to neointimal hyperplasia after balloon- or stent-induced injury but also that temporal and spatial patterns of leukocyte infiltration vary with different forms of arterial injury.

An Integrated View of In-Stent Restenosis

Figure 4 illustrates an integrated view of the pathophysiological processes underlying in-stent restenosis. Figure 4A illustrates a mature atherosclerotic plaque. The initial events immediately after stent placement result in deendothelialization and the deposition of a layer of platelets and fibrin at the injured site (Figure 4B). Activated platelets express adhesion molecules such as P-selectin and glycoprotein (GP) I β α , which attach to circulating leukocytes via platelet receptors such as P-selectin glycoprotein ligand (Figure 4C with inset) and begin a process of rolling along the injured surface. Under the influence of cytokines (Figure 4C), leukocytes bind tightly to the leukocyte integrin (ie, Mac-1) class of adhesion molecules via direct attachment to platelet receptors such as GP I β α and through cross-linking with fibrinogen to the GP IIb/IIIa receptor (Figure 4D, inset). The migration of leukocytes across the platelet-fibrin layer and into the tissue is driven by chemical gradients of cytokines released from SMCs and resident leukocytes (Figure 4C and 4D). Growth factors are released from platelets, leukocytes, and SMCs, which influence the proliferation and migration of SMCs from the media into the neointima (Table, Figure 4D). The resultant neointima consists of SMCs, extracellular matrix, and macrophages recruited over several weeks (Figure 4E). Over even longer periods of time (Figure 4F), there is a shift to fewer cellular elements with, and greater production of, extracellular matrix. In addition, there is eventual reendothelialization of at least part of the injured vessel surface.

Implications for Antirestenotic Therapies

The data presented in the present review suggest that an anti-inflammatory approach may be an effective way to suppress neointimal growth and restenosis after percutaneous intervention in humans. Indeed, a shared feature of many promising therapies in clinical trials currently is an anti-inflammatory potential. For example, sirolimus, which has shown remarkable efficacy against restenosis in a coated stent design,⁵³ is a known inhibitor of regulatory elements of the cell cycle. However, it also possesses important anti-inflammatory properties, as evidenced by its initial develop-

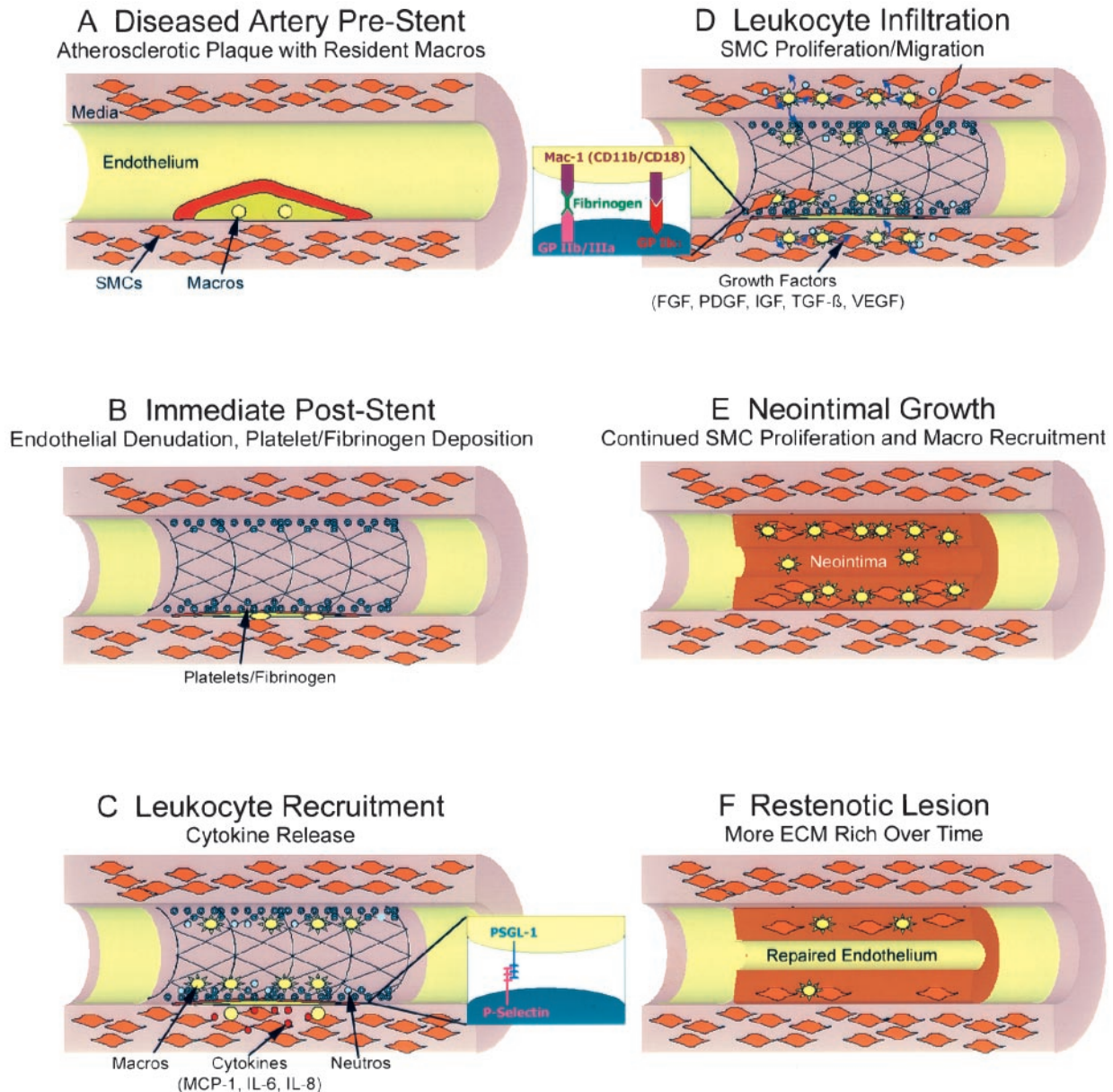


Figure 4. A, Mature atherosclerotic plaque before intervention. B, Immediate result of stent placement with endothelial denudation and platelet/fibrinogen deposition. C and D, Leukocyte recruitment, infiltration, and SMC proliferation and migration in the days after injury. E, Neointimal thickening in the weeks after injury, with continued SMC proliferation and monocyte recruitment. F, Long-term (weeks to months) change from a predominantly cellular to a less cellular and more ECM-rich plaque.

ment as an antifungal agent and its current use as an immunomodulatory agent in the treatment of renal transplant rejection.⁵⁴ In a porcine model of stent injury, sirolimus-coated stents, compared with bare metal stents, were associated with reduced vessel wall protein expression of the cytokines MCP-1 and IL-6.⁵⁵ Similarly, the microtubule stabilizer paclitaxel, a promising therapy for restenosis via stent-based delivery, is known to interfere with SMC proliferation and migration through its effect on microtubules.⁵⁴ However, there are also data to suggest that paclitaxel affects leukocyte function. Interestingly, this appears at least in part to be mediated through the interference of cytoskeletal interactions with the integrin class of adhesion molecules.⁵⁶ The effects of brachytherapy on inflammation have not been

studied in detail, although one report suggests that delayed endothelialization after brachytherapy in a porcine model may actually increase the inflammatory burden.⁵⁷

The data presented in the present review also suggest that there are important differences in the temporal and spatial pattern of inflammation between stent and balloon injury that must be taken into account when anti-restenotic therapies are designed. Specifically, the inflammatory response engendered by a stent is prolonged and rich in cells of the monocyte/macrophage lineage. Therefore, anti-inflammatory therapies may have to be delivered over a prolonged period of time and also must include anti-macrophage activity. This requirement for prolonged activity makes all the more appealing the use of the stent itself as a platform for delivery.

Major Growth Factors/Cytokines Involved in the Restenotic Process

Growth Factor	Source (Within Vessel Wall)	Putative Action
PDGF A and B	Platelets	SMC migration and proliferation
	Endothelial cells	
	SMCs	
FGF (acidic and basic)	SMCs	SMC proliferation
Insulin-like growth factors	SMCs	SMC proliferation especially as comitogen with PDGF and FGF
Transforming growth factor β	Endothelial cells	SMC proliferation and inhibition
	SMCs	
Vascular endothelial growth factor	Endothelial cells	Endothelialization and angiogenesis
Cytokine	Source (Within Vessel Wall)	Classification and Putative Action
MCP-1	Macrophages	A C-C chemokine predominately involved in monocyte recruitment
	SMCs	
	Endothelial cells	
	Fibroblasts	
IL-8	Macrophages, T-cells, PMNs	A C-X-C chemokine predominately involved in neutrophil and monocyte recruitment
	SMCs	
	Endothelial cells	
	Fibroblasts	
IL-6	Macrophages, T-cells, PMNs	A member of the IL-6 family of cytokines involved in acute phase reactant expression; specific vascular effects unknown.
	SMCs	
	Endothelial cells	
	Fibroblasts	

PDGF indicates platelet-derived growth factor; FGF, fibroblast growth factor; PMN, polymorphonuclear leukocytes..

A final word should be said regarding the lack of efficacy of prior anti-inflammatory drugs in human trials of restenosis. In a broad sense, one can implicate either a lack of understanding of the biological responses to injury, use of the wrong drug, or an incomplete understanding of pharmacokinetics and pharmacodynamics. First, many of these trials were conducted in an era of predominant balloon angioplasty rather than stenting, which, as we have described in the present review, causes a fundamental change in the nature of the vascular biological response to injury. Heparin provides an example for which pharmacokinetics and pharmacodynamics may be the issue. Heparin is the archetypical modulator of vascular repair after vascular injury in a variety of animal models. It has long been known that heparin inhibits SMC proliferation and neointimal hyperplasia independent of its anticoagulant properties.⁵⁸ Multiple studies have also demonstrated that heparin also is a powerful anti-inflammatory agent and that this characteristic is intimately related to its antiproliferative properties in animal studies of vascular injury.^{33,59} However, human trials of subcutaneous heparin after percutaneous intervention have proven ineffective in preventing restenosis.⁶⁰ An explanation of this paradox is suggested by data from prior animal studies suggesting that the efficacy of heparin against neointimal growth is critically dependent on the type of vascular injury imposed⁶¹ and the duration and frequency of heparin administration.⁵⁰ These data suggest that human studies of heparin after percutaneous

intervention may have suffered from an insufficient dosing interval and duration of administration. Although less completely studied than heparin, it is possible that pharmacokinetic and pharmacodynamic issues may also lie behind the failure of tranilast, a drug showing efficacy in animal models⁶² but not in a large-scale human trial.⁶³

Conclusions

An evolving understanding of the pathogenesis of restenosis has placed inflammation at the center of the process. Much of our early understanding of this process was based on studies of balloon angioplasty. It is imperative to understand that the placement of a stent, now the predominant therapy in humans, profoundly alters all elements of vascular repair, particularly inflammatory processes. These differences must be understood and incorporated into the development of antirestenotic therapies in the stent era.

References

1. Gruntzig AR, Senning A, Siegenthaler WE. Nonoperative dilatation of coronary-artery stenosis: percutaneous transluminal coronary angioplasty. *N Engl J Med.* 1979;301:61–68.
2. Bourassa MG, Wilson JW, Detre KM, Kelsey SF, Robertson T, Passamani ER. Long-term follow-up of coronary angioplasty: the 1977–1981 National Heart, Lung, and Blood Institute registry. *Eur Heart J.* 1989;10(suppl G):36–41.
3. McBride W, Lange RA, Hillis LD. Restenosis after successful coronary angioplasty: pathophysiology and prevention. *N Engl J Med.* 1988;318:1734–1737.

4. Faxon DA, Weber VJ, Haudenschild C, Gottsman SB, McGovern WA, Ryan TJ. Acute effects of transmural angioplasty in three experimental models of atherosclerosis. *Arteriosclerosis*. 1982;2:125-133.
5. Faxon DP, Sanborn TA, Weber VJ, Haudenschild C, Gottsman SB, McGovern WA, Ryan TJ. Restenosis following transluminal angioplasty in experimental atherosclerosis. *Arteriosclerosis*. 1984;4:189-195.
6. Faxon DP, Sanborn TA, Haudenschild CC, Ryan TJ. Effect of antiplatelet therapy on restenosis after experimental angioplasty. *Am J Cardiol*. 1984;53:72C-76C.
7. Forrester JS, Fishbein M, Helfant R, Fagin J. A paradigm for restenosis based on cell biology: clues for the development of new preventive therapies. *J Am Coll Cardiol*. 1991;17:758-769.
8. Marcus AJ. Thrombosis and inflammation as multicellular processes: significance of cell-cell interactions. *Semin Hematol*. 1994;31:261-269.
9. Libby P, Simon DI. Inflammation and thrombosis: the clot thickens. *Circulation*. 2001;103:1718-1720.
10. Diacovo TG, Roth SJ, Buccola JM, Bainton DF, Springer TA. Neutrophil rolling, arrest, and transmigration across activated, surface-adherent platelets via sequential action of P-selectin and the beta 2-integrin CD11b/CD18. *Blood*. 1996;88:146-157.
11. Yeo EL, Sheppard JA, Feuerstein IA. Role of P-selectin and leukocyte activation in polymorphonuclear cell adhesion to surface adherent activated platelets under physiologic shear conditions (an injury vessel wall model). *Blood*. 1994;83:2498-2507.
12. Ott I, Neumann FJ, Gawaz M, Schmitt M, Schomig A. Increased neutrophil-platelet adhesion in patients with unstable angina. *Circulation*. 1996;94:1239-1246.
13. Furman MI, Benoit SE, Barnard MR, Valeri CR, Borbone ML, Becker RC, Hechtman HB, Michelson AD. Increased platelet reactivity and circulating monocyte-platelet aggregates in patients with stable coronary artery disease. *J Am Coll Cardiol*. 1998;31:352-358.
14. Rollins BJ. Monocyte chemoattractant protein 1: a potential regulator of monocyte recruitment in inflammatory disease. *Mol Med Today*. 1996;2:198-204.
15. Webb LMC, Ehrenguber MU, Clark-Lewis I, Baggiolini M. Binding to heparan sulfate or heparin enhances neutrophil responses to interleukin 8. *Proc Natl Acad Sci U S A*. 1993;90:7158-7162.
16. Huo Y, Weber C, Forlow SB, Sperandio M, Thatte J, Mack M, Jung S, Littman DR, Ley K. The chemokine KC, but not monocyte chemoattractant protein-1, triggers monocyte arrest on early atherosclerotic endothelium. *J Clin Invest*. 2001;108:1307-1314.
17. Ross R. Atherosclerosis: an inflammatory disease. *N Engl J Med*. 1999;340:115-126.
18. Farb A, Weber DK, Kolodgie FD, Burke AP, Virmani R. Morphological predictors of restenosis after coronary stenting in humans. *Circulation*. 2002;105:2974-2980.
19. Moreno PR, Bernardi VH, Lopez-Cuellar J, Newell JB, McMellon C, Gold HK, Palacios IF, Fuster V, Fallon JT. Macrophage infiltration predicts restenosis after coronary intervention in patients with unstable angina. *Circulation*. 1996;94:3098-3102.
20. Neumann F-J, Ott I, Gawaz M, Puchner G, Schomig A. Neutrophil and platelet activation at balloon-injured coronary artery plaque in patients undergoing angioplasty. *J Am Coll Cardiol*. 1996;27:819-824.
21. Mickelson JK, Lakkis NM, Villarreal-Levy G, Hughes B, Smith CW. Leukocyte activation with platelet adhesion after coronary angioplasty: a mechanism for recurrent disease. *J Am Coll Cardiol*. 1996;28:345-353.
22. Inoue T, Sakai Y, Morooka S, Hayashi T, Takayanagi K, Takabatake Y. Expression of polymorphonuclear leukocyte adhesion molecules and its clinical significance in patients treated with percutaneous transluminal coronary angioplasty. *J Am Coll Cardiol*. 1996;28:1127-1133.
23. Pietersma A, Kofflard M, de Wit LEA, Stinjen T, Koster JF, Serruys P, Sluiter W. Late lumen loss after coronary angioplasty is associated with the activation status of circulating phagocytes before treatment. *Circulation*. 1995;91:1320-1325.
24. Cipollone F, Marini M, Fazio M, Pini B, Iezzi A, Reale M, Paloscia L, Materazzo G, D'Annunzio E, Conti P, Chiarelli F, Cuccurullo F, Mezzetti A. Elevated circulating levels of monocyte chemoattractant protein-1 in patients with restenosis after coronary angioplasty. *Arterioscler Thromb Vasc Biol*. 2001;21:327-334.
25. Gaspardone A, Crea F, Versaci F, Tomai F, Pellegrino A, Chiariello L, Gioffre PA. Predictive value of C-reactive protein after successful coronary-artery stenting in patients with stable angina. *Am J Cardiol*. 1998;82:515-518.
26. Cybulsky MI, Gimbrone MAJ. Endothelial expression of a mononuclear leukocyte adhesion molecule during atherogenesis. *Science*. 1991;251:788-791.
27. Li H, Cybulsky M, Gimbrone MA, Libby P. An atherogenic diet induces VCAM-1, a cytokine-regulatable mononuclear leukocyte adhesion molecule, in rabbit endothelium. *Arterioscler Thromb*. 1992;13:197-204.
28. Li H, Cybulsky MI, Gimbrone MA Jr, Libby P. Inducible expression of vascular cell adhesion molecule-1 by vascular smooth muscle cells in vitro and within rabbit atheroma. *Am J Pathol*. 1993;143:1551-1559.
29. Richardson M, Hadcock SJ, DeReske M, Cybulsky MI. Increased expression in vivo of VCAM-1 and E-selectin by the aortic endothelium of normolipemic and hyperlipemic diabetic rabbits. *Arterioscler Thromb*. 1994;14:760-769.
30. Walpole PL, Gotlieb AI, Cybulsky MI, Langille L. Expression of ICAM-1 and VCAM-1 and monocyte adherence in arteries exposed to altered shear stress. *Arterioscler Thromb Vasc Biol*. 1995;15:2-10.
31. Tanaka H, Sukhova GK, Swanson SJ, Clinton SK, Ganz P, Cybulsky MI, Libby P. Sustained activation of vascular cells and leukocytes in the rabbit aorta after balloon injury. *Circulation*. 1993;88:1788-1803.
32. Rogers C, Welt FGP, Karnovsky MJ, Edelman ER. Monocyte recruitment and neointimal hyperplasia in rabbits: coupled inhibitory effects of heparin. *Arterioscler Thromb Vasc Biol*. 1996;16:1312-1318.
33. Welt FGP, Edelman ER, Simon DI, Rogers C. Neutrophil, not macrophage, infiltration precedes neointimal thickening in balloon-injured arteries. *Arterioscler Thromb Vasc Biol*. 2000;20:2553-2558.
34. Rogers C, Edelman ER, Simon DI. A mAb to the beta2-leukocyte integrin Mac-1 (CD11b/CD18) reduces intimal thickening after angioplasty or stent implantation in rabbits. *Proc Natl Acad Sci U S A*. 1998;95:10134-10139.
35. Mori E, Komori K, Yamaoka T, Tani M, Kataoka C, Takeshita A, Usui M, Egashira K, Sugimachi K. Essential role of monocyte chemoattractant protein-1 in development of restenotic changes (neointimal hyperplasia and constrictive remodeling) after balloon angioplasty in hypercholesterolemic rabbits. *Circulation*. 2002;105:2905-2910.
36. Libby P, Schwartz D, Brogi E, Tanaka H, Clinton S. A cascade model for restenosis. *Circulation*. 1992;86(suppl III):III-47-III-52.
37. Jorgensen L, Grothe AG, Groves HM, Kinlough-Rathbone RL, Richardson M, Mustard JF. Sequence of cellular responses in rabbit aortas following one and two injuries with a balloon catheter. *Br J Exp Pathol*. 1988;69:473-486.
38. Richardson M, Hatton MW, Buchanan MR, Moore S. Wound healing in the media of the normolipemic rabbit carotid artery injured by air drying or by balloon catheter de-endothelialization. *Am J Pathol*. 1990;137:1453-1465.
39. Kockx MM, De Meyer GR, Jacob WA, Bult H, Herman AG. Triphasic sequence of neointimal formation in the cuffed carotid artery of the rabbit. *Arterioscler Thromb*. 1992;12:1447-1457.
40. Lloyd AR, Oppenheim JJ. Poly's lament: the neglected role of the polymorphonuclear neutrophil in the afferent limb of the immune response. *Immunol Today*. 1992;13:169-172.
41. Cole CW, Makhoul RG, McCann RL, O'Malley MK, Hagen PO. A neutrophil derived factor(s) stimulates [3H]thymidine incorporation by vascular smooth muscle cells in vitro. *Clin Invest Med*. 1988;11:62-67.
42. Mintz GS, Popma JJ, Pichard AD, Kent KM, Satler LF, Wong C, Hong MK, Kovach JA, Leon MB. Arterial remodeling after coronary angioplasty: a serial intravascular ultrasound study. *Circulation*. 1996;94:35-43.
43. Fischman DL, Leon MB, Baim DS, Schatz RA, Savage MP, Penn IM, Detre K, Veltri L, Ricci DR, Nobuyoshi M, Cleman MW, Heuser RR, Almond D, Teirstein PS, Fish RD, Colombo A, Brinker J, Moses J, Shalovich A, Hirshfeld J, Bailey S, Ellis S, Rake R, Goldberg S. A randomized comparison of coronary artery-stent placement and balloon angioplasty in the treatment of coronary artery disease. *N Engl J Med*. 1994;331:496-501.
44. Serruys PW, de Jaegere P, Kiemeneij F, Macaya C, Rutsch W, Heyndrickx G, Emanuelsson H, Marco J, Legrand V, Mateme P, Belardi J, Sijwart U, Colombo A, Goy J, van den Heuvel P, Delcan J, Morel M. A comparison of balloon-expandable-stent implantation with balloon angioplasty in patients with coronary artery disease. *N Engl J Med*. 1994;331:489-495.
45. Hoffmann R, Mintz GS, Dussaillant GR, Popma JJ, Pichard AD, Satler LF, Kent KM, Griffin J, Leon MB. Patterns and mechanisms of in-stent restenosis: a serial intravascular ultrasound study. *Circulation*. 1996;94:1247-1254.
46. Inoue T, Sohma R, Miyazaki T, Iwasaki Y, Yaguchi I, Morooka S. Comparison of activation process of platelets and neutrophils after cor-

- onary stent implantation versus balloon angioplasty for stable angina pectoris. *Am J Cardiol.* 2000;86:1057–1062.
47. Clowes AW, Clowes MM. Kinetics of cellular proliferation after arterial injury: II. Inhibition of smooth muscle cell growth by heparin. *Lab Invest.* 1985;52:611–616.
 48. Clowes AW, Clowes MM. Kinetics of cellular proliferation after arterial injury, IV: heparin inhibits rat smooth muscle cell mitogenesis and migration. *Circ Res.* 1986;58:839–845.
 49. Rogers C, Edelman ER. Controlled release of heparin reduces neointimal hyperplasia in stented rabbit arteries: ramifications for local therapy. *J Interv Card.* 1992;5:195–202.
 50. Edelman ER, Karnovsky MJ. Contrasting effects of the intermittent and continuous administration of heparin in experimental restenosis. *Circulation.* 1994;89:770–776.
 51. Paolini JF, Kjelsberg MA, Edelman ER, Rogers CDK. Sustained expression of chemokines monocyte chemoattractant protein-1 and interleukin-8 after stent- but not balloon-induced arterial injury. *J Am Coll Cardiol.* 2000;35:15. Abstract.
 52. Horvath C, Welt FG, Nedelman M, Rao P, Rogers C. Targeting CCR2 or CD18 inhibits experimental in-stent restenosis in primates: inhibitory potential depends on type of injury and leukocytes targeted. *Circ Res.* 2002;90:488–494.
 53. Morice MC, Serruys PW, Sousa JE, Fajadet J, Ban Hayashi E, Perin M, Colombo A, Schuler G, Barragan P, Guagliumi G, Molnar F, Falotico R. A randomized comparison of a sirolimus-eluting stent with a standard stent for coronary revascularization. *N Engl J Med.* 2002;346:1773–1780.
 54. Oberhoff M, Herdeg C, Baumbach A, Karsch KR. Stent-based antirestenotic coatings (sirolimus/paclitaxel). *Catheter Cardiovasc Interv.* 2002;55:404–408.
 55. Suzuki TM, Kopia GP, Hayashi S, Bailey LRA, Llanos GP, Wilensky RM, Klugherz BDM, Papandreou GP, Narayan PP, Leon MBM, Yeung ACM, Tio FM, Tsao PSP, Falotico RP, Carter AJD. Stent-based delivery of sirolimus reduces neointimal formation in a porcine coronary model. *Circulation.* 2001;104:1188–1193.
 56. Zhou X, Li J, Kucik DF. The microtubule cytoskeleton participates in control of beta2 integrin avidity. *J Biol Chem.* 2001;276:44762–44769.
 57. Kollum M, Cottin Y, Chan RC, Kim H, Bhargava B, Vodovotz Y, Waksman R. Delayed re-endothelialization and T-cell infiltration following intracoronary radiation therapy in the porcine model. *Int J Radiat Oncol Biol Phys.* 2001;50:495–501.
 58. Guyton JR, Rosenberg RD, Clowes AW, Karnovsky MJ. Inhibition of rat arterial smooth muscle cell proliferation by heparin: in vivo studies with anticoagulant and nonanticoagulant heparin. *Circ Res.* 1980;46:625–634.
 59. Rogers C, Karnovsky MJ, Edelman ER. Heparin's inhibition of monocyte adhesion to experimentally injured arteries matches its antiproliferative effects. *Circulation.* 1993;88(suppl I):I-370. Abstract.
 60. Ellis SG, Roubin GS, Wilentz J, Douglas JS Jr, King SB III. Effect of 18- to 24-hour heparin administration for prevention of restenosis after uncomplicated coronary angioplasty. *Am Heart J.* 1989;117:777–782.
 61. Rogers C, Karnovsky MJ, Edelman ER. Inhibition of experimental neointimal hyperplasia and thrombosis depends on the type of vascular injury and the site of drug administration. *Circulation.* 1993;88:1215–1221.
 62. Ishiwata S, Verheye S, Robinson KA, Salame MY, de Leon H, King SB III, Chronos NA. Inhibition of neointima formation by tranilast in pig coronary arteries after balloon angioplasty and stent implantation. *J Am Coll Cardiol.* 2000;35:1331–1337.
 63. SoRelle R. Late-breaking clinical trials at the American Heart Association's Scientific Sessions 2001. *Circulation.* 2001;104:E9046–E9048.