

Targeting CCR2 or CD18 Inhibits Experimental In-Stent Restenosis in Primates

Inhibitory Potential Depends on Type of Injury and Leukocytes Targeted

Christopher Horvath,* Frederick G.P. Welt,* Mark Nedelman, Patricia Rao, Campbell Rogers

Abstract—A central role for leukocytes in neointimal hyperplasia after arterial injury is suspected. However, the relative importance of neutrophils and monocytes in balloon or stent-induced injury are not well understood, and mechanistic targeting of leukocyte recruitment or function is crude. We determined the temporal and spatial distribution of different leukocytes after balloon and stent-induced injury in primate iliac arteries. Based on these data, we targeted neutrophil and monocyte recruitment selectively after angioplasty or stent implantation and demonstrated that monocyte-specific blockade achieved via blockade of the MCP-1 receptor CCR2, was effective at reducing neointimal hyperplasia after stenting. In contrast, combined neutrophil and monocyte blockade achieved by targeting the leukocyte β_2 -integrin β -subunit CD18 was required to reduce neointimal hyperplasia after balloon injury. Distinct patterns of leukocyte infiltration in balloon versus stent-injured arteries predict distinct mechanisms for antiinflammatory strategies targeting neutrophils or monocytes in primates and may assist design of effective clinical strategies for optimizing vascular interventions. (*Circ Res.* 2002;90:488-494.)

Key Words: stents ■ leukocytes ■ primates

There is increasing evidence from both clinical and animal studies that leukocytes play a central role in restenosis after balloon angioplasty and stent implantation. Although a variety of antiinflammatory therapies have proven effective at reducing neointimal hyperplasia in nonprimate animal models after arterial injury, few have been tested in primate models or in clinical practice. Important differences exist between the superficial injury associated with balloon-induced denudation and the deep sustained injury associated with stent implantation that may influence the effectiveness of strategies against restenosis.

In stented rabbit arteries, targeted inhibition of leukocyte recruitment with a monoclonal antibody against the leukocyte β_2 integrin Mac-1 (CD11b/CD18) profoundly reduced neointimal hyperplasia.¹ Surprisingly, this approach was equally effective at reducing neointimal hyperplasia in balloon-injured arteries, a model devoid of monocyte infiltration but possessing transient neutrophil accumulation closely coupled with medial smooth muscle cell proliferation.² These data suggest that leukocyte infiltration is causally related to neointimal hyperplasia after balloon- or stent-induced injury, but that temporal and spatial patterns of leukocyte infiltration

vary with different forms of arterial injury. The hypotheses of the current study were as follows: (1) the kinetics of inflammatory cell recruitment differ markedly between stent and balloon-induced injury, and (2) on this basis, targeting specific recruitment mechanisms will produce different effects in different forms of injury.

Materials and Methods

Surgical and Tissue Retrieval Techniques

The first experiment was designed to examine early leukocyte recruitment patterns after arterial injury. Six male cynomolgus monkeys (*Macaca fascicularis*) underwent balloon dilatation and stent implantation (described later in this section). Animals received daily aspirin (≈ 40 mg, orally), beginning on Day -3 and continuing until euthanasia. On Day 1, animals received a single prophylactic injection of benzathine/procaine penicillin-G (42 000 IU/kg, IM) and were preanesthetized (ketamine HCl, 10 mg/kg, IM; atropine SO₄, 0.04 mg/kg, IM), then intubated and maintained in anesthesia with isoflurane. Animals were euthanized at day 4 (n=2), day 7 (n=2), and day 14 (n=2) after injury.

In the second experiment, animals were randomized on the basis of body weight to 3 groups to undergo balloon injury and stent implantation and receive treatment with either an irrelevant murine IgG2a isotype control mAb (S-S.1, n=5 animals), an anti-human

Original received March 7, 2001; resubmission received December 20, 2001; revised resubmission received January 17, 2002; accepted January 17, 2002.

From the Department of Medicine, Cardiac Catheterization Laboratory, Cardiovascular Division, Brigham and Women's Hospital, Harvard Medical School, Boston, Mass and the Harvard/MIT Division of Health Sciences and Technology, Massachusetts Institute of Technology, Cambridge, Mass (F.G.P.W., C.R.); the West Roxbury Veteran's Affairs Medical Center (F.G.P.W.), West Roxbury, Mass; and the Clinical Investigator Training Program, Harvard/MIT Division of Health Sciences and Technology-Beth Israel Deaconess Medical Center, in collaboration with Pfizer Inc (F.G.P.W.), Millennium Pharmaceuticals (C.H., P.R.), Cambridge, Mass, and Primedica Corporation (M.N.), Worcester, Mass.

*Both authors contributed equally to this study.

Correspondence to Frederick G.P. Welt, MD, Harvard-MIT Division of Health Sciences and Technology, MIT, 16-343, Cambridge, MA 02139. E-mail welt@mediaone.net

© 2002 American Heart Association, Inc.

Circulation Research is available at <http://www.circresaha.org>

DOI: 10.1161/hh0402.105956

CCR2 mAb (1D9, $n=5$ animals), or an anti-human CD18 mAb (IB4, $n=5$ animals). Animals received an intravenous loading dose (5 mg/kg in 30 mL via 30-minute infusion) on Day -1 , followed by daily SC injections (1 mg/kg in 3 mL) on Days 1 to 13. Animals were euthanized at day 29.

The right carotid artery was surgically exposed, and under fluoroscopic guidance, a guidewire (Guidant/ACS) was used to facilitate passage of a 6Fr guide catheter antegrade to the abdominal aortic bifurcation. The luminal diameter of each iliac artery was measured angiographically (see Quantitative Angiography section). Heparin was then administered (150 U/kg, IV) with subsequent doses to maintain activated clotting time (ACT) values greater than 250 seconds. An 80 cm, 3Fr Fogarty balloon embolectomy catheter was passed into one iliac artery to a level approximately 4 cm distal to the aortic bifurcation. The balloon was then withdrawn inflated over an approximately 3-cm section of artery 3 times. This procedure was repeated in the contralateral iliac artery. A balloon dilation catheter (Cordis Corp.), chosen to achieve a balloon:artery ratio of 1.1 to 1.2 at 6 atm pressure, was fitted with a balloon-expandable 7-mm stent (half of a 15-mm CS15-030, Palmaz-Schatz Crown balloon-expandable stent, Cordis Corp.) and passed into an iliac artery to the level of the midpoint of endothelial denudation and expanded to 6 atm. After 30 seconds, the balloon was deflated and the catheter withdrawn. This procedure was repeated in the contralateral iliac artery. The carotid artery was ligated and the incision closed. Animals received a single injection of buprenorphine (0.01 mg/kg, IM) after completion of the procedures.

After preterminal angiography via left carotid artery cutdown on day 29, animals were euthanized by deep anesthesia (sodium pentobarbital, 35 mg/kg, IV), followed by exsanguination. Pressure perfusion of the aorta and iliac arteries was accomplished with lactated Ringer's solution, followed by 0.4% PFA for ≈ 5 minutes at 100 mm Hg. Right and left iliac arteries were immersed in 0.4% PFA.

In vivo portions of this study were conducted at Primedica (Worcester, Mass), a testing facility accredited by the Association for Assessment and Accreditation of Laboratory Animal Care and licensed by the United States Department of Agriculture (USDA) to conduct research in laboratory animals in compliance with the Animal Welfare Act, USDA regulations, and the National Research Council guidelines. Anesthesia and euthanasia were performed in accordance with American Veterinary Medical Association guidelines. Animal activities described in the study protocol were reviewed and approved by the Institutional Animal Care and Use Committee before study initiation.

Antibody Production and Characterization

Three murine IgG2a monoclonal antibodies (mAbs) were used in these studies: S-S.1, an anti-sheep red blood cell mAb (American Type Culture Collection; ATCC No. TIB-111) used as an irrelevant isotype-matched control mAb; IB4, an anti-human CD18 mAb that recognizes CD18 on nonhuman primate leukocytes (ATCC No. HB-10164); and 1D9, an anti-human CCR2 antibody (Millennium Pharmaceuticals), that recognizes CCR2 on nonhuman primate leukocytes. The endotoxin level of all mAbs was less than 1 EU/mL.

Prior to use, the specificity of 1D9 and IB4 mAbs for their respective cellular targets was confirmed on cynomolgus monkey leukocytes by flow cytometry; S-S.1 was shown to have no cross-reactivity with monkey leukocytes by flow cytometry and tissue staining. Using cynomolgus monkey and human lymphoblasts in vitro, 1D9 was shown to saturate CCR2, prevent binding of human MCP-1, and prevent chemotaxis to MCP-1 at concentrations of ≈ 5 $\mu\text{g/mL}$. In a pilot study in cynomolgus monkeys, a single dose of 5 mg/kg 1D9 was shown to saturate CCR2 on cynomolgus monkey monocytes through 72 hours. IB4 was shown in vitro to prevent adhesion of human neutrophils to fibrinogen-coated plates at a concentration of 1 $\mu\text{g/mL}$. The dose regimen (5 mg/kg IV followed by 1 mg/kg SC QD for 13 days) was designed to provide serum mAb concentrations >5 $\mu\text{g/mL}$ at the time of injury and >1 $\mu\text{g/mL}$ for up to 14 days.

Study Procedures

Blood samples were collected periodically for assay of serum mAb levels (pharmacokinetics), leukocyte target saturation and return of free sites (pharmacodynamics), anti-mAb antiglobulin response (immunogenicity), and routine hematology and serum chemistry.

Quantitative Angiography

Prior to angioplasty, nitroglycerine (50 μg , IA) was administered, followed by contrast injection (Omnipaque, iohexol injection, Nycomed). For each artery, angiography was performed prior to injury (Before), at the time of stent deployment (Deploy), 10 minutes after deployment (After), and on day 29 (Follow-up).

Recorded images were replayed on a larger video screen and quantitative angiography measurements of the mid-stent luminal diameter performed in a blinded fashion using digital calipers. These measurements allowed calculation of acute luminal gain (ALG=Deploy–Before), late luminal loss (LLL=After–Follow-up), and the loss:gain index (LLL/ALG).³

Tissue Processing

Stented segments were embedded in methyl methacrylate mixed with *n*-butyl methacrylate (Sigma Chemical Co)^{4,5} to allow for sectioning through metal stent struts. Balloon-injured segments were paraffin embedded.

Histological and Immunocytochemical Analysis

To minimize sampling error, an average value for each stent-injured vessel was calculated after analysis of cross-sections from the proximal, middle, and distal portions of each stent. Tissue and cell structures were identified in histological sections by staining with Verhoeff's tissue elastin stain or hematoxylin and eosin. Neointimal and medial cross-sectional areas were measured by computer-assisted digital planimetry. The luminal surface was examined for adherent leukocytes categorized as either monocytoid or polymorphonuclear under 600 \times magnification.⁵ For balloon-injured segments, cross-sectional luminal, intimal, and medial areas were measured morphometrically. The total vessel area and intima:media ratio were then calculated.

For stented segments, average intimal thickness was calculated (as the difference between average intimal and luminal radii). To verify that the degree of stent-induced injury was comparable among groups, an average depth of injury score for each cross-section was calculated.⁶

Species-specific antibodies were utilized to immunocytochemically identify primate macrophages (HAM-56, Dako Corp) in both paraffin-embedded and methyl methacrylate-embedded specimens. A mAb against human neutrophil elastase (NP57, Dako Corp) was used to identify neutrophils in paraffin-embedded samples. This antibody did not prove effective in methyl methacrylate-embedded specimens. Monkey spleen was used as a positive control. Standard immunocytochemical protocols were used in conjunction with heat-induced epitope retrieval as previously described.⁵ The samples were examined for staining of neutrophils in balloon-injured specimens and monocytes in both balloon-injured and stented specimens. The number of cells present were assessed quantitatively utilizing a scale from 0 (no cells) to 1 (scattered cells), 2 (focal deposits), and 3 (diffuse intense infiltration).

Pharmacokinetics, Pharmacodynamics, and Immunogenicity

Serum S-S.1, 1D9, or IB4 mAb levels were determined by an enzyme-linked immunosorbent assay (ELISA) for murine IgG. The relative amount of 1D9 or IB4 bound to appropriate leukocyte subsets (monocytes for CCR2 and neutrophils and monocytes for CD18) was measured flow cytometrically (mean channel fluorescence; MFC) as an indicator of the relative in vivo saturation of each target. Relative amounts of free CCR2 or CD18 on leukocytes were determined by "spiking" paired blood samples with a supersaturating concentration of the appropriate mAb prior to processing as above. The difference in staining intensity (MCF value) between the sample

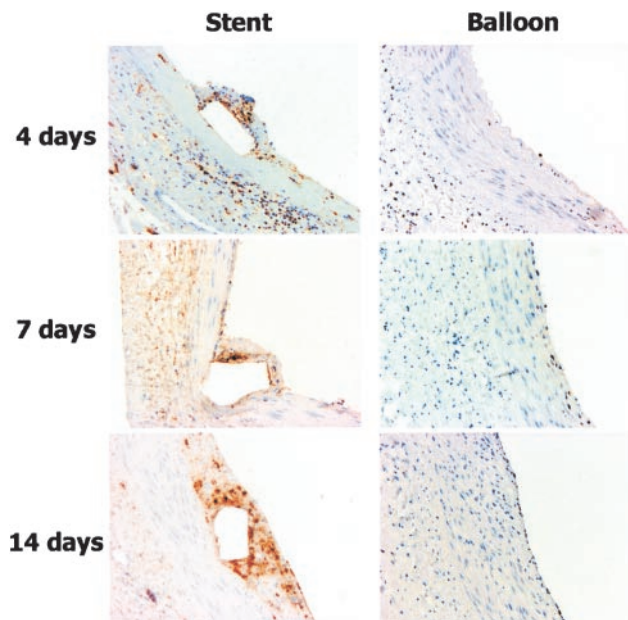


Figure 1. Photomicrograph shows immunostaining for macrophages in balloon-injured and stented arteries at days 4, 7, and 14 after injury.

spiked with mAb (complete saturation) and the unspiked sample (in vivo saturation) was representative of the relative amount of free CCR2 or CD18 available. This same process was applied to samples from animals treated with S-S.1 to assess nonspecific staining. Serum anti-mAb antibody titers were determined by bridging ELISAs designed to detect both anti-idiotypic and anti-isotypic antibodies.

Control of Bias

Animals were randomly assigned to treatment groups. A blinded observer performed quantitative angiography measurements and computer-aided morphometric measurements.

Statistics

All data are presented as mean±SEM. Comparisons between treatment groups used an unpaired, 2-tailed *t* test. Where multiple comparisons were examined, a 1-way ANOVA with a Dunnett’s test for multiple comparisons was used. Values of *P*<0.05 were considered significant.

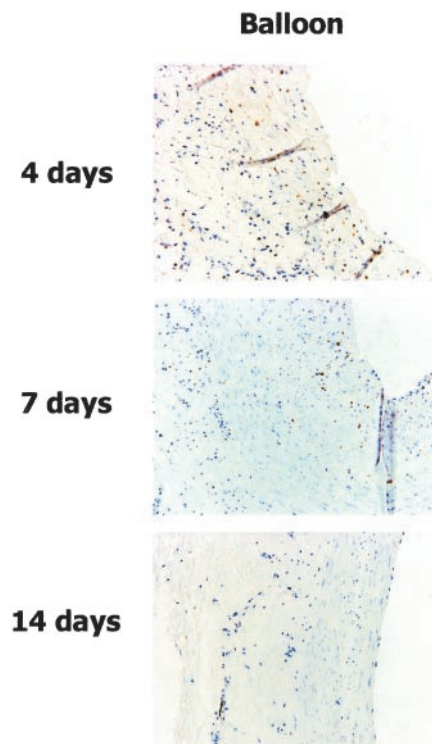


Figure 2. Photomicrograph shows immunostaining for neutrophils in balloon-injured arteries at days 4, 7, and 14 after injury.

Results

Time Course Studies

At day 4, there was little intima evident in balloon-injured arteries. In stented arteries, a layer of thrombus and cellular material surrounding the stent struts constituted the neointima. Adherent leukocytes of both granulocyte and monocyte morphology were evident in both injury groups, but more were evident on the luminal surface of stented arteries (140±24 versus 14±7 cells/section, *P*<0.001). Immunocytochemical examination at day 4 (Figure 1) revealed sparse infiltrative macrophages within the media of balloon-injured arteries, with substantially more cells identified within the media and neointima of stented arteries (Table 1). Both

TABLE 1. Immunohistochemical Evaluation of Macrophage Content

Group	Day 4		Day 7		Day 14	
	Grade	<i>P</i>	Grade	<i>P</i>	Grade	<i>P</i>
Neointima						
Stent	1.8±0.3	NA	2±0.3	<0.03	3±0	<0.003
Balloon	NA		1.3±0.3		1±0.4	
Media						
Stent	1±0	<0.03	1.5±0.3	<0.02	1.3±0.3	<0.04
Balloon	0.3±0.3		0.3±0.3		0.3±0.3	
Adventitia						
Stent	2.3±0.3	NS	3±0	NS	2.8±0.3	NS
Balloon	2.8±0.3		2.8±0.3		2.8±0.3	

P values are for balloon vs stent.

balloon-injured and stented arteries contained numerous macrophages within the adventitia. Immunohistochemistry for neutrophils showed many neutrophils within the media of balloon-injured arteries (Figure 2).

At day 7, a cellular neointima was evident in both balloon-injured and stented arteries. Adherent leukocytes remained more abundant in stented than in balloon-injured specimens (42 ± 12 versus 4 ± 2 cells/section, $P < 0.03$). Sparse neointimal and medial macrophages were identified in balloon-injured arteries but substantially more were seen in stented arteries. Many macrophages were still evident within the adventitia of both balloon-injured and stented arteries. Immunohistochemistry for neutrophils at day 7 showed many neutrophils within the neointima of balloon-injured arteries and few within the media (Figure 2).

By day 14, few adherent cells were still identifiable on the lumen of stented arteries or balloon-injured arteries (8 ± 5 versus 0 cells/section, $P = \text{NS}$). Macrophages were still abundant within the neointima of stented arteries although only sparse in the neointima of balloon-injured arteries. Substantial numbers of macrophages were still evident within the adventitia of both balloon-injured and stented arteries at day 14. There were virtually no neutrophils observed within the neointima, media, or adventitia of balloon-injured arteries.

In summary, the inflammatory response in balloon-injured arteries was limited to early (7 days) neutrophil infiltration with only sparse macrophage accumulation within the media and neointima. In contrast, in stented arteries, there was a progressive and sustained accumulation of macrophages.

Antibody Administration Experiments

Safety

There were no treatment-related effects on vital signs, body weight, or clinical course during the study. There were no adverse events associated with surgical wounds or clinical pathology parameters. Leukocyte counts were affected by CD18 blockade (see next section).

Pharmacokinetics, Pharmacodynamics, and Immunogenicity

Administration of initial loading doses (day -1) of 1D9 or IB4 resulted in peak serum concentrations at the time of angioplasty and stent deployment the following day (Figures 3A and 3B). Subsequent subcutaneous doses maintained serum concentrations $> 3.9 \pm 2.0$ or 1.4 ± 0.6 $\mu\text{g/mL}$, respectively, through day 8 (Figures 3A and 3B). These serum mAb concentrations were associated with high levels of 1D9 bound to monocytes immediately after dosing and undetectable levels of free CCR2 on monocytes through day 8 (Figure 3B). The same was true for binding of CD18 on both neutrophils (Figure 3A) and monocytes (data not shown). CD18 blockade induced leukocytosis on day 8 (Figure 3C). Leukocyte counts were not affected by 1D9 (data not shown). By day 15, serum mAb levels were virtually undetectable, despite continuation of dosing from day -1 to 13. This loss of detectable circulating mAbs, coinciding with the return of free CCR2 on monocytes and free CD18 on neutrophils and monocytes and the return of peripheral blood leukocyte counts to normal values, is attributed to the onset of marked neutralizing anti-mAb antibody responses (Figure 3C). These data indi-

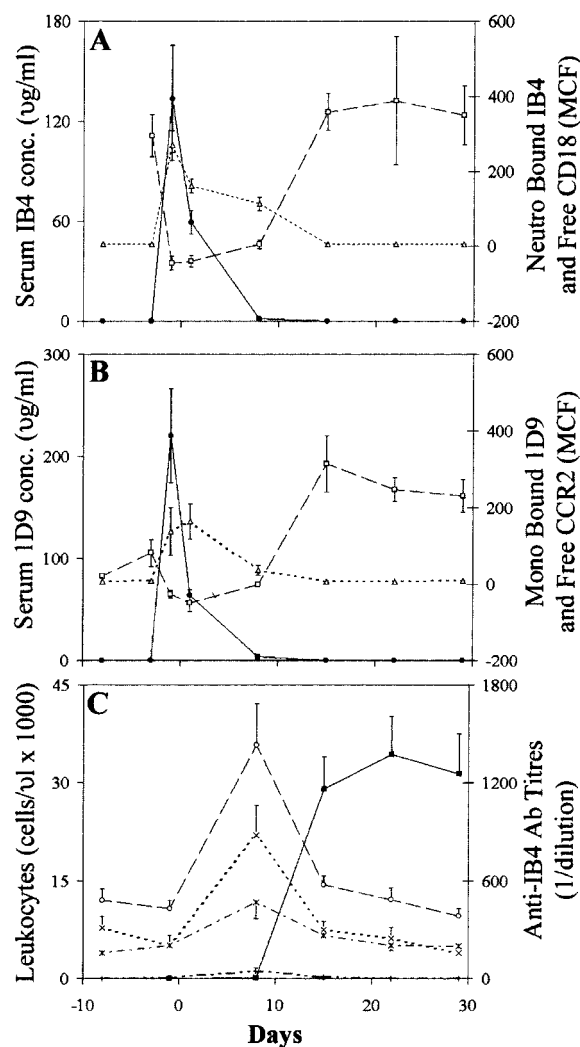


Figure 3. A, Relationship between serum IB4 concentration (●—●), IB4 bound to neutrophils (△--△), and free CD18 on neutrophils (□--□). B, Relationship between serum 1D9 concentration (●—●), 1D9 bound to monocytes (△--△) and free CCR2 on monocytes (□--□). C, The relationship between peripheral blood leukocyte counts and serum anti-IB4 antibody responses; leukocytes (○--○), neutrophils (x--x), lymphocytes (*--*), monocytes (+--+), and neutralizing anti-IB4 antibodies titers (■—■). Mean \pm SEM.

cate that effective CCR2 or CD18 blockade was achieved and maintained through day 8. After day 8, the immunogenicity of these murine mAbs likely nullified their activity.

Efficacy

Quantitative Angiography

Administration of IB4 and 1D9 reduced the loss:gain index (LLL/ALG) of stented segments compared with control (1D9: 0.24 ± 0.53 versus 1.51 ± 0.40 , $P = 0.07$; and IB4: 0.15 ± 0.48 versus 1.51 ± 0.40 , $P < 0.05$).

Morphometric Analysis

Morphometric analysis of neointimal hyperplasia for balloon-injured and stented iliac artery segments are presented in

TABLE 2. Morphometric Evaluation of Neointimal Hyperplasia at Day 29 After Injury

Group	n	Intimal Area, mm ²	Intima:Media Ratio
Balloon-only injury			
Control	10	0.32±0.07	0.52±0.10
1D9	10	0.45±0.13	0.85±0.27
1B4	10	0.19±0.03*	0.19±0.04†
	n	Injury Score	Intimal Thickness, mm
Balloon+stent injury			
Control	10	0.20±0.04	0.25±0.03
1D9	10	0.15±0.03	0.14±0.02*
1B4	10	0.19±0.04	0.13±0.02†

**P*<0.05; †*P*<0.01 vs control. Mean±SEM.

Table 2. Balloon-induced neointimal hyperplasia (I:M ratio) was significantly reduced by CD18 blockade with IB4 (63%, *P*<0.05), but not by CCR2 blockade with 1D9 (Figures 4A and 5). For stented segments, analysis of deep injury severity scores indicated no difference between groups. Control animals developed marked in-stent neointimal hyperplasia (Figures 4B and 5). In contrast, neointimal thickening was significantly reduced by both blockade of CCR2 on monocytes (46%, *P*<0.05) and CD18 on leukocytes (48%, *P*<0.01) (Figures 4B and 5).

Immunocytochemistry

At day 29 after injury, few tissue macrophages were identified by HAM-56 staining within the media, neointima, or

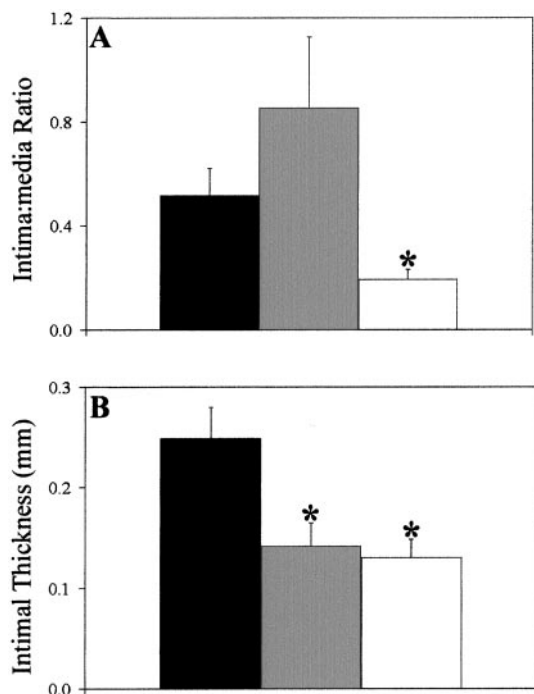


Figure 4. A, Intima:media area ratio in primate iliac arteries undergoing balloon denudation only. Compared with controls (black bars), IB4 (white bars) resulted in significant reduction of neointimal hyperplasia. 1D9 (gray bars) was not effective. B, Intimal thickness in portions of iliac arteries undergoing balloon endothelial denudation and stent placement. Both IB4 and 1D9 reduced neointimal growth. **P*<0.05; mean±SEM.

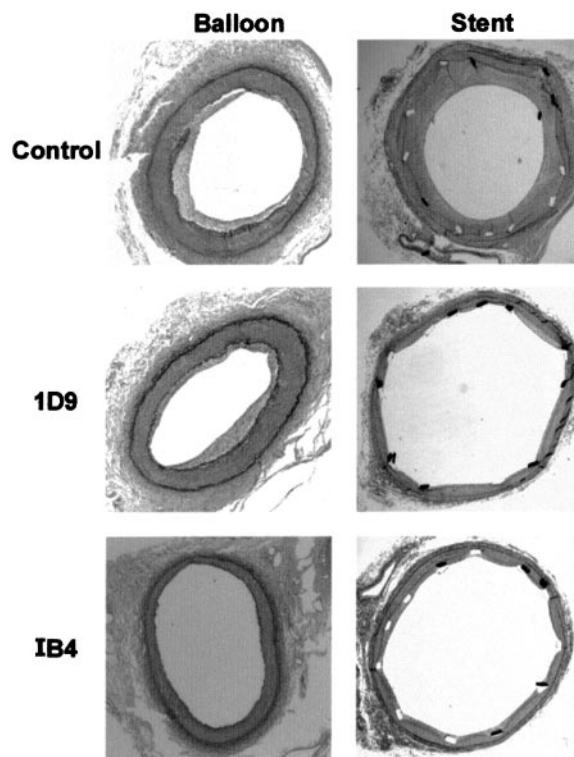


Figure 5. Photomicrographs of cross-sections of primate iliac arteries. Shown are both balloon-injured and stented sections treated with either control IgG, 1D9, or IB4.

adventitia of balloon-injured or stented arteries regardless of treatment group (all grade 0 or 1, data not shown). Immunohistochemistry for neutrophil elastase revealed no neutrophils within balloon-injured arteries. At this late time point, despite the greater than 2-week period after cessation of therapy, no adherent inflammatory cells were observed.

Discussion

Leukocytes have long been known to play an important causative role in the development of human atherosclerosis.⁷ In addition, there is increasing evidence to suggest that both monocytes and neutrophils play a role in restenosis after percutaneous intervention and in experimentally induced arteriopathies.^{1,8-12} Our data demonstrate that there is a distinct pattern of leukocyte infiltration that distinguishes the superficial injury associated with simple balloon-induced de-endothelialization from the deep sustained injury associated with stent implantation. In a primate iliac artery model, balloon injury was associated with early and transient infiltration of neutrophils with sparse macrophage accumulation, whereas stent implantation is associated with sustained recruitment of macrophages over days to weeks. These data suggest that an antiinflammatory strategy directed against monocytes would be effective against stent- but not balloon-induced neointimal hyperplasia. This hypothesis was tested in the same primate model by targeting monocytes but not neutrophils (1D9, anti-CCR2) or by targeting both neutrophils and monocytes (IB4, anti-CD18). As hypothesized, CCR2 blockade was effective at inhibiting neointimal hyperplasia after stent-induced injury only, although CD18 blockade was

effective against neointimal hyperplasia after both balloon- or stent-induced injuries.

Role of Leukocytes in Atherosclerosis and Experimentally Induced Arteriopathies

Cells of monocyte lineage have long been observed in both human atherosclerotic lesions^{13,14} and experimentally induced arteriopathies.^{5,15–17} We have previously reported infiltration and accumulation of monocytes in rabbit iliac arteries after stent-induced arterial injury.⁵ Further, inhibition of monocyte accumulation through administration of heparin or specific interruption of leukocyte adhesion and activation via the β_2 integrin Mac 1 (CD11b/CD18) reduced monocyte accumulation coincident with inhibition of neointimal hyperplasia, thus suggesting a causative role for monocytes in neointimal hyperplasia after stent-induced arterial injury.^{1,5}

There have been several reports documenting infiltration of neutrophils after a variety of forms of arterial injury in rabbit models.^{18–21} We reported infiltration of neutrophils, but not macrophages, after balloon injury of rabbit iliac arteries and have demonstrated that inhibition of neutrophil accumulation with heparin or a mAb against Mac-1 is correlated with an inhibition of medial smooth muscle cell (SMC) proliferation, suggesting a causative role for neutrophils in neointimal hyperplasia after balloon injury.² Furthermore, mice lacking Mac-1 developed less intimal thickening after denudation than wild-type animals despite a relative paucity of mononuclear cells.¹²

There have been several studies involving administration of antibodies against CD18 in animal models of restenosis. Using a model of a repetitively electrically stimulated rabbit carotid artery, Kling et al²² demonstrated evidence of infiltration of both neutrophils and monocytes after injury. Administration of a mAb against CD18 (60.3) abolished neutrophil infiltration and partially abolished mononuclear cell invasion, but had no effect on early SMC migration from media to neointima. In contrast, Golino et al²³ reported that administration of a mAb against CD18 (R15.7) in a rabbit carotid model of injury involving placement of a constrictor around the vessel produced significant inhibition of neointimal hyperplasia. Van Put et al²⁴ also studied the effect of a mAb against CD18 (R15.7) in a collar-induced injury model in rabbit iliac arteries. They found plentiful neutrophils and small numbers of monocytes (CD14 positive cells) after injury. Anti-CD18 therapy reduced neutrophil accumulation but had no effect on early (3 day) intimal thickening or smooth muscle cell number. Failure to demonstrate efficacy with anti-CD18 mAbs in these studies might be related to use of a mAb that recognizes an epitope of CD18 not essential for functional activity in the species or model tested or to use of a functionally blocking mAb at insufficient levels of exposure. The latter possibility might occur if the dose administered produced low levels of blockade, short duration of coverage, or precipitated a rapid neutralizing antiglobulin response. On this note, none of these studies assessed the degree of CD18 saturation or inhibition *ex vivo* and none reported whether neutralizing antibodies developed.

Cipollone et al²⁵ have demonstrated upregulated levels of MCP-1 following percutaneous intervention in humans and found that MCP-1 levels correlate with risk for restenosis. Similarly, there are several studies of strategies against MCP-1

in animal models that show prevention of atherosclerotic lesion development or inhibition of post-injury neointimal growth.^{26–30} In addition, our laboratory has demonstrated sustained upregulation of MCP-1 expression in stented rabbit iliac arteries (14 days) after injury in contrast to balloon-injured arteries.³¹ These data are consistent with our findings that the anti-CCR2 mAb 1D9 is effective against neointimal hyperplasia in stented arteries, a model in which monocytes predominate.

Primate Model of Restenosis

Although many strategies have proven effective against restenosis in nonprimate animal models, there have been few studies in primates. Several studies have shown efficacy of antibodies against platelet-derived growth factor in limiting balloon-induced neointimal thickening in nonhuman primates.^{32–34} We are aware of no published data to date reporting efficacy of any agent at limiting intimal thickening after stent-induced injury in nonhuman primates.³⁵ We now present data demonstrating suppression of neointimal hyperplasia in primates after balloon injury (IB4) and stent-induced injury (IB4 and 1D9).

Durability of Effect

Of importance in studies of therapies to reduce neointimal thickening is the possibility of a rebound growth of neointimal hyperplasia after cessation of therapy, which might render these therapies ineffective over time. In the present study, we document the presence of neutralizing antibodies to 1D9 and IB4 at approximately day 8. Despite the presence of neutralizing antibodies at day 8 and the cessation of therapy at day 13, the inhibitory effects of these agents were still observed at day 29, suggesting that these strategies provide a durable effect. It is unknown what the consequences of this antibody response would be for readministration of these therapies. Nor is it clear whether such a brief period of leukocyte inhibition would be sufficient to effect restenosis in humans. However, it should be emphasized that due to the use of a murine antibody in a primate, antigenic responses are not unexpected. One would expect that humanized monoclonal antibodies such as those typically utilized in human trials would not likely engender this response.

Limitations

Of particular relevance to the inflammatory response after vascular injury is hyperlipidemia. Elevated lipid levels, particularly of low-density lipoprotein, profoundly influence the number and type of leukocytes recruited, and play a well-recognized role in human atherosclerosis. For these reasons, it will be important to extend observations from the present study to hyperlipidemic animal models.

Conclusions

The present study builds on evidence that inflammatory cells are important mediators of restenosis after vascular injury and suggests that there are important differences in the temporal and cellular characteristics of the inflammatory response to vascular injury that follows balloon denudation or implantation of a sustained indwelling stent. The inflammatory response after balloon injury is a transient phenomenon consisting predominantly of an influx of neutrophils. In contrast, the inflammatory response after stent implantation is more prolonged and involves

sustained accumulation of macrophages. Based on these data, we designed a model in which antiinflammatory agents with specificity against different leukocyte classes were given after balloon or stent injury demonstrating a pivotal role of neutrophils in balloon injury and macrophages in stent injury. Our data suggest that an understanding of the vascular biology specific to different types of arterial injury is necessary in order to design effective antiproliferative therapies. In addition, our data suggests that therapy directed against CD18 and CCR2 may be effective against restenosis in humans.

Acknowledgments

This work was supported in part by grants from the National Institutes of Health (HL 03104). We are grateful to Daren Bergman, Prudence Bird, Charlene Corbett, Ken Ganley, Luis Guerrero, Shixin Qin, James Rottman, and Philip Seifert for their assistance.

References

- Rogers C, Edelman ER, Simon DI. A mAb to the β 2-leukocyte integrin Mac-1 (CD11b/CD18) reduces intimal thickening after angioplasty or stent implantation in rabbits. *Proc Natl Acad Sci U S A*. 1998;95:10134–10139.
- Welt FGP, Edelman ER, Simon DI, Rogers C. Neutrophil, not macrophage, infiltration precedes neointimal thickening in balloon-injured arteries. *Arterioscler Thromb Vasc Biol*. 2000;20:2553–2558.
- Kuntz RE, Safian RD, Levine MJ, Reis GJ, Diver DJ, Baim DS. Novel approach to the analysis of restenosis after the use of three new coronary devices. *J Am Coll Cardiol*. 1992;19:1493–1499.
- Wolf E, Roser K, Hahn M, Welkerling H, Delling G. Enzyme and immunohistochemistry on undecalcified bone and bone marrow biopsies after embedding in plastic: a new embedding method for routine application. *Virchows Archiv A Pathol Anat*. 1992;420:17–24.
- Rogers C, Welt FGP, Karnovsky MJ, Edelman ER. Monocyte recruitment and neointimal hyperplasia in rabbits: coupled inhibitory effects of heparin. *Arterioscler Thromb Vasc Biol*. 1996;16:1312–1318.
- Schwartz RS, Huber KC, Murphy JG, Edwards WD, Camrud AR, Vlietstra RE, Holmes DR. Restenosis and proportional neointimal response to coronary artery injury: results in a porcine model. *J Am Coll Cardiol*. 1992;19:267–274.
- Ross R. The pathogenesis of atherosclerosis: an update. *N Eng J Med*. 1986;314:488–500.
- Moreno PR, Bernardi VH, Lopez-Cuellar J, Newell JB, McMellon C, Gold HK, Palacios IF, Fuster V, Fallon JT. Macrophage infiltration predicts restenosis after coronary intervention in patients with unstable angina. *Circulation*. 1996;94:3098–3102.
- Neumann FJ, Ott I, Gawaz M, Puchner G, Schomig A. Neutrophil and platelet activation at balloon-injured coronary artery plaque in patients undergoing angioplasty. *J Am Coll Cardiol*. 1996;27:819–824.
- Rogers C, Karnovsky MJ, Edelman ER. Heparin's inhibition of monocyte adhesion to experimentally injured arteries matches its antiproliferative effects. *Circulation*. 1993;88(suppl):I-370. Abstract.
- Yasukawa H, Imaizumi T, Matsuoka H, Nakashima A, Morimatsu M. Inhibition on intimal hyperplasia after balloon injury by antibodies to intercellular adhesion molecule-1 and lymphocyte function-associated antigen-1. *Circulation*. 1997;95:1515–1522.
- Simon DI, Chen Z, Seifert P, Edelman ER, Ballantyne CM, Rogers C. Decreased neointimal formation in mac-1^{-/-} mice reveals a role for inflammation in vascular repair after angioplasty. *J Clin Invest*. 2000;105:293–300.
- Jonasson L, Holm J, Skalli O, Bondjers G, Hansson GK. Regional accumulations of T cells, macrophages, and smooth muscle cells in the human atherosclerotic plaque. *Arteriosclerosis*. 1986;6:131–138.
- Saphir O, Gore I. Evidence for an inflammatory basis of coronary arteriosclerosis in the young. *Arch Pathol*. 1950;49:418–426.
- Joris I, Zand T, Nunnari JJ, Krolkowski FJ, Majno G. Studies in the pathogenesis of atherosclerosis: I, adhesion and emigration of mononuclear cells in the aorta of hypercholesterolemic rats. *Am J Pathol*. 1983;113:341–358.
- Jerome WG, Lewis JC. Early atherogenesis in white carneau pigeons. *Am J Pathol*. 1984;116:56–68.
- Hansson GK, Björnheden T, Bylock A, Bondjers G. Fc-dependent binding of monocytes to areas with endothelial injury in the rabbit aorta. *Exp Mol Pathol*. 1981;34:264–280.
- Jorgensen L, Grothe AG, Groves HM, Kinlough-Rathbone RL, Richardson M, Mustard JF. Sequence of cellular responses in rabbit aortas following one and two injuries with a balloon catheter. *Br J Exp Pathol*. 1988;69:473–486.
- Richardson M, Hatton MW, Buchanan MR, Moore S. Wound healing in the media of the normolipemic rabbit carotid artery injured by air drying or by balloon catheter de-endothelialization. *Am J Pathol*. 1990;137:1453–1465.
- Kockx MM, De Meyer GR, Jacob WA, Bult H, Herman AG. Triphasic sequence of neointimal formation in the cuffed carotid artery of the rabbit. *Arterioscler Thromb*. 1992;12:1447–1457.
- Kockx MM, De Meyer GR, Andries LJ, Bult H, Jacob WA, Herman AG. The endothelium during cuff-induced neointima formation in the rabbit carotid artery. *Arterioscler Thromb*. 1993;13:1874–1884.
- Kling D, Fingerle J, Harlan JM, Lobb RR, Lang F. Mononuclear leukocytes invade rabbit arterial intima during thickening formation via CD18- and VLA-4-dependent mechanisms and stimulate smooth muscle migration. *Circ Res*. 1995;77:1121–1128.
- Golino P, Ambrosio G, Ragni M, Cirillo P, Esposito N, Willerson JT, Rothlein R, Petrucci L, Condorelli M, Chiariello M, Buja LM. Inhibition of leukocyte and platelet adhesion reduces neointimal hyperplasia after arterial injury. *Thromb Haemost*. 1997;77:783–788.
- Van Put DJ, Van Osselaer N, De Meyer GR, Andries LJ, Kockx MM, De Clerck LS, Bult H. Role of polymorphonuclear leukocytes in collar-induced intimal thickening in the rabbit carotid artery. *Arterioscler Thromb Vasc Biol*. 1998;18:915–921.
- Cipollone F, Marini M, Fazio M, Pini B, Iezzi A, Reale M, Paloscia L, Materazzo G, D'Annunzio E, Conti P, Chiarelli F, Cuccurullo F, Mezzetti A. Elevated circulating levels of monocyte chemoattractant protein-1 in patients with restenosis after coronary angioplasty. *Arterioscler Thromb Vasc Biol*. 2001;21:327–334.
- Furukawa Y, Matsumori A, Ohashi N, Shioi T, Ono K, Harada A, Matsushima K, Sasayama S. Anti-monocyte chemoattractant protein-1/monocyte chemoattractant and activating factor antibody inhibits neointimal hyperplasia in injured rat carotid arteries. *Circ Res*. 1999;84:306–314.
- Gu L, Okada Y, Clinton SK, Gerard C, Sukhova GK, Libby P, Rollins BJ. Absence of monocyte chemoattractant protein-1 reduces atherosclerosis in low density lipoprotein receptor-deficient mice. *Mol Cell*. 1998;2:275–281.
- Boring L, Gosling J, Cleary M, Charo IF. Decreased lesion formation in CCR2^{-/-} mice reveals a role for chemokines in the initiation of atherosclerosis. *Nature*. 1998;394:894–897.
- Feng AN, Chen YL, Chen YT, Ding YZ, Lin SJ. Red wine inhibits monocyte chemotactic protein-1 expression and modestly reduces neointimal hyperplasia after balloon injury in cholesterol-Fed rabbits. *Circulation*. 1999;100:2254–2259.
- Ni W, Egashira K, Kitamoto S, Chu Kataoka, Koyanagi M, Inoue S, Imaizumi K, Akiyama C, Nishida K-i, Takeshita A. New anti-monocyte chemoattractant protein-1 gene therapy attenuates atherosclerosis in apolipoprotein E-knockout mice. *Circulation*. 2001;103:2096–2101.
- Paolini JF, Kjelsberg MA, Edelman ER, Rogers CDK. Sustained expression of chemokines monocyte chemoattractant protein-1 and interleukin-8 after stent- but not balloon-induced arterial injury. *J Am Coll Cardiol*. 2000;35(suppl):15. Abstract.
- Hart CE, Kraiss LW, Vergel S, Gilbertson D, Kenagy R, Kirkman T, Crandall DL, Tickle S, Finney H, Yarranton G, Clowes AW. PDGF β receptor blockade inhibits intimal hyperplasia in the baboon. *Circulation*. 1999;99:564–569.
- Giessa NA, Marjjanowski MM, McCook O, Hancock A, Ramakrishnan V, Fretto LJ, Chen C, Kelly AB, Koziol JA, Wilcox JN, Hanson SR. The role of α and β platelet-derived growth factor receptor in the vascular response to injury in nonhuman primates. *Arterioscler Thromb Vasc Biol*. 1999;19:900–909.
- Davies MG, Owens EL, Mason DP, Lea H, Tran PK, Vergel S, Hawkins SA, Hart CE, Clowes AW. Effect of platelet-derived growth factor receptor- α and - β blockade on flow-induced neointimal formation in endothelialized baboon vascular grafts. *Circ Res*. 2000;86:779–786.
- Deitch JS, Williams JK, Adams MR, Fly CA, Herrington DM, Jordan RE, Nakada MT, Jakubowski JA, Geary RL. Effects of β 3-integrin blockade (c7E3) on the response to angioplasty and intra-arterial stenting in atherosclerotic nonhuman primates. *Arterioscler Thromb Vasc Biol*. 1998;18:1730–1737.